

**Certificate Course in
Primary Care Dermoscopy
(5) Quiz in Primary Care Dermoscopy**

Antonio An Tung Chuh

**MD(HK) MRCP(UK) FRCP FRCPE FRCPG FRCPI FRCPCH
FRCGP FRACGP FHKCFP MFM(Monash) FHKAM(Family Medicine)**

DCH(Lond) DCH(Irel) DCCH(Edin) DFM(Monash)

DipDerm(Glasg) DPDerm(Wales) Dip G-U Med(LAS)

Honorary Clinical Associate Professor in Family Medicine, University of Hong Kong

Adjunct Clinical Associate Professor in Family Medicine

The Chinese University of Hong Kong

Visiting Professor in Primary Care, University of Zürich

Visiting Professor in Primary Care, University of Kiel



**Hong Kong Society of
Primary Care Dermoscopy**

Disclaimer

Knowledge and the best practice in dermoscopy, dermatology, skin surgery, family medicine, and primary care medicine are constantly changing. As new research broadens our understanding, changes in research methods, practices, or clinical managements may become necessary.

Clinicians must always rely on their knowledge, skills, and experience in evaluating and using any method described in this presentation and the correlated materials. They should also be mindful for their own safety and safety to patients.

To the fullest extent of the law, the author(s) and associated societies of this presentation and correlated materials do not assume liability for any injury to patients as a matter of products liability, negligence, or otherwise, or from any use of ideas contained in this presentation and the correlated materials.

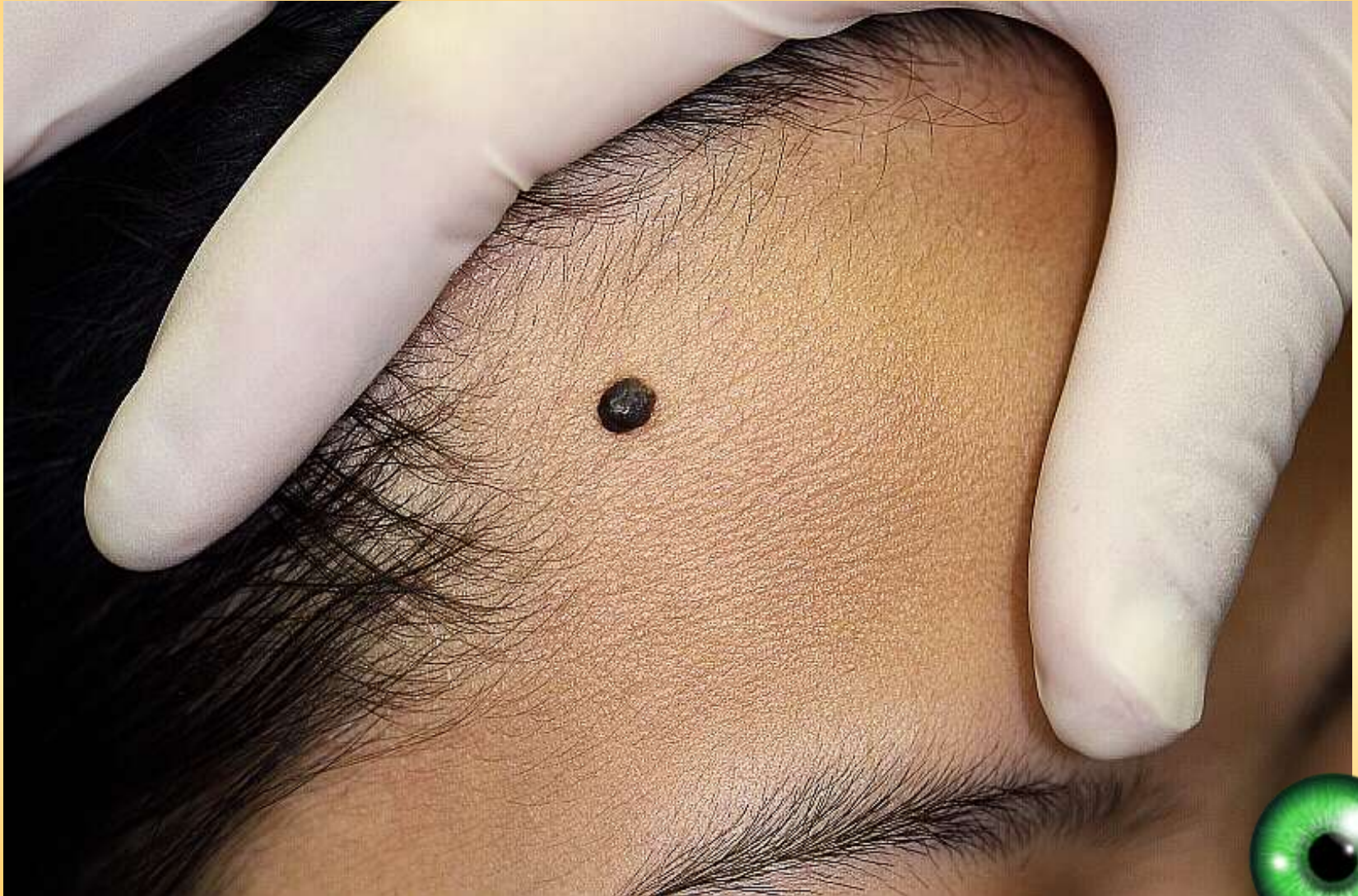Dr Antonio Chuh and the Hong Kong Society of Primary Care Dermoscopy hold the copyright of all the materials and ideas in this presentation and correlated materials.



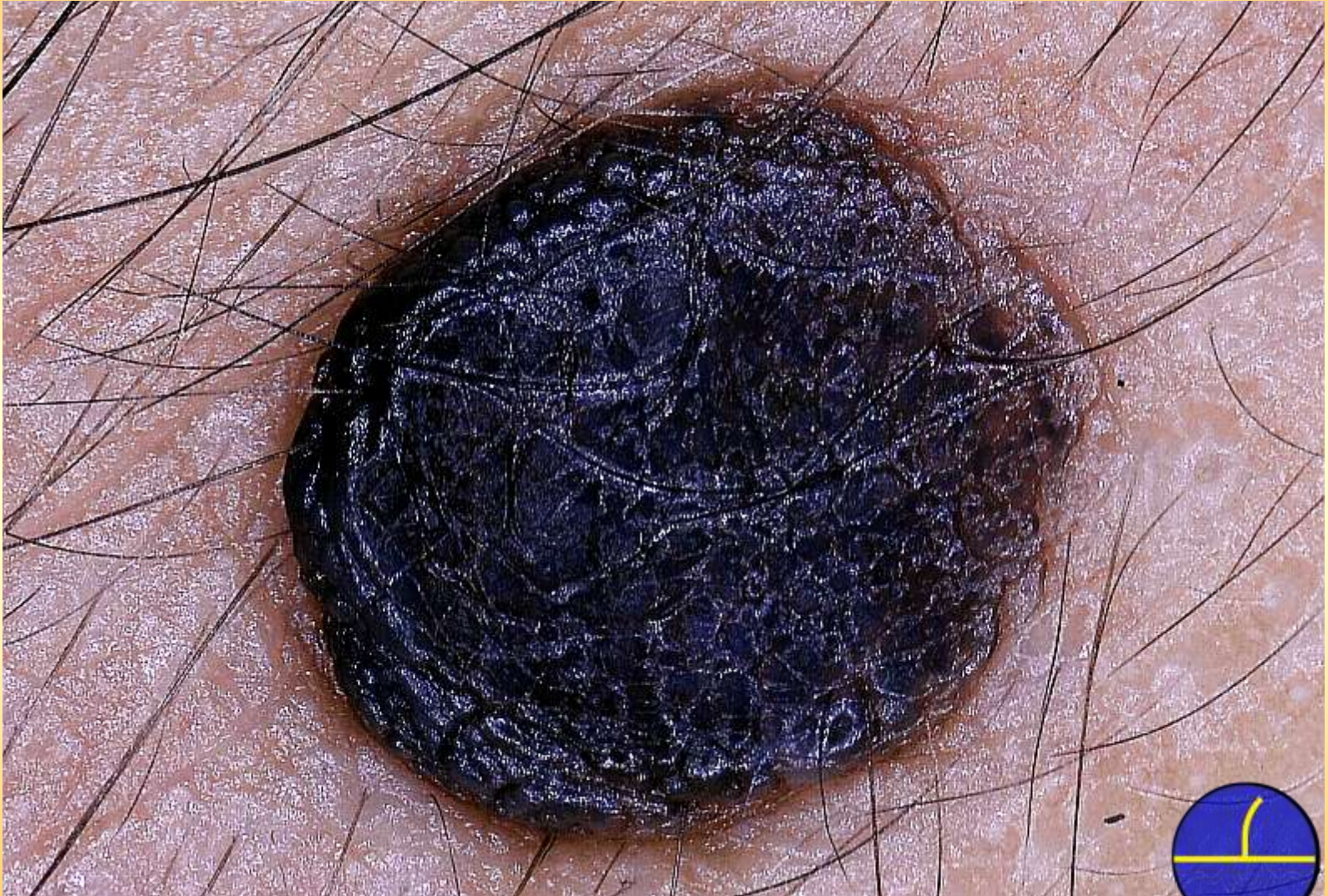Board of Advisors

- **Prof Peter Fung** (Medical Physics), Emeritus Professor, Department of Medicine, The University of Hong Kong
- **Prof Gabriel Sciallis** (Primary Care and Dermatology), Mayo Medical School, Mayo Clinic, Minnesota, US
- **Prof Regina Fölster-Holst** (Dermatology and Dermoscopy), Universitätsklinikum Schleswig-Holstein, Germany
- **Prof Vijay Zawar** (Primary Care and Dermoscopy), Dr Vasantryo Pawar Medical College, India
- **Prof Werner Kempf** (Dermatopathology), University Hospital Zürich, Switzerland

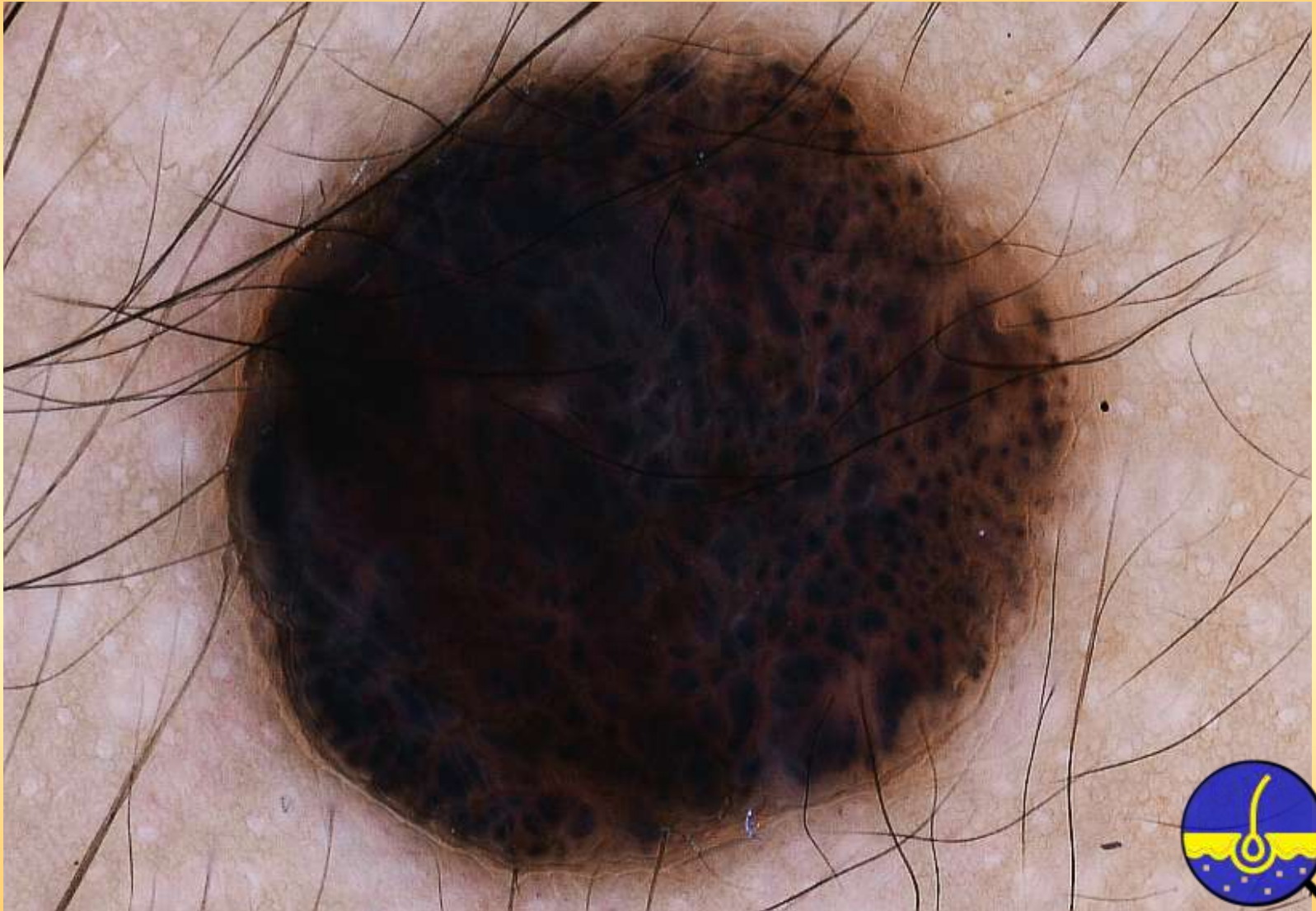Quiz – dermoscopy



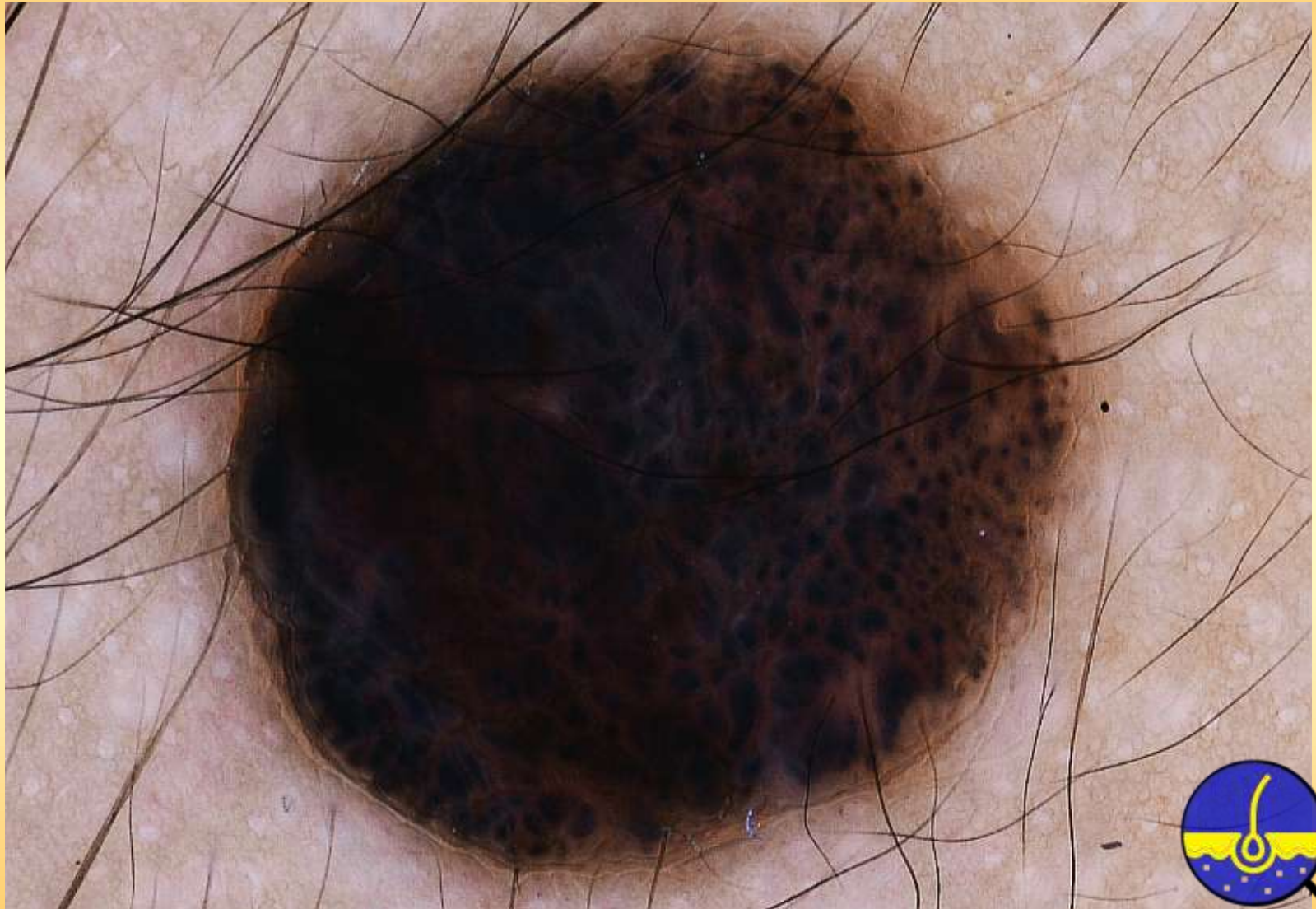Quiz – dermoscopy



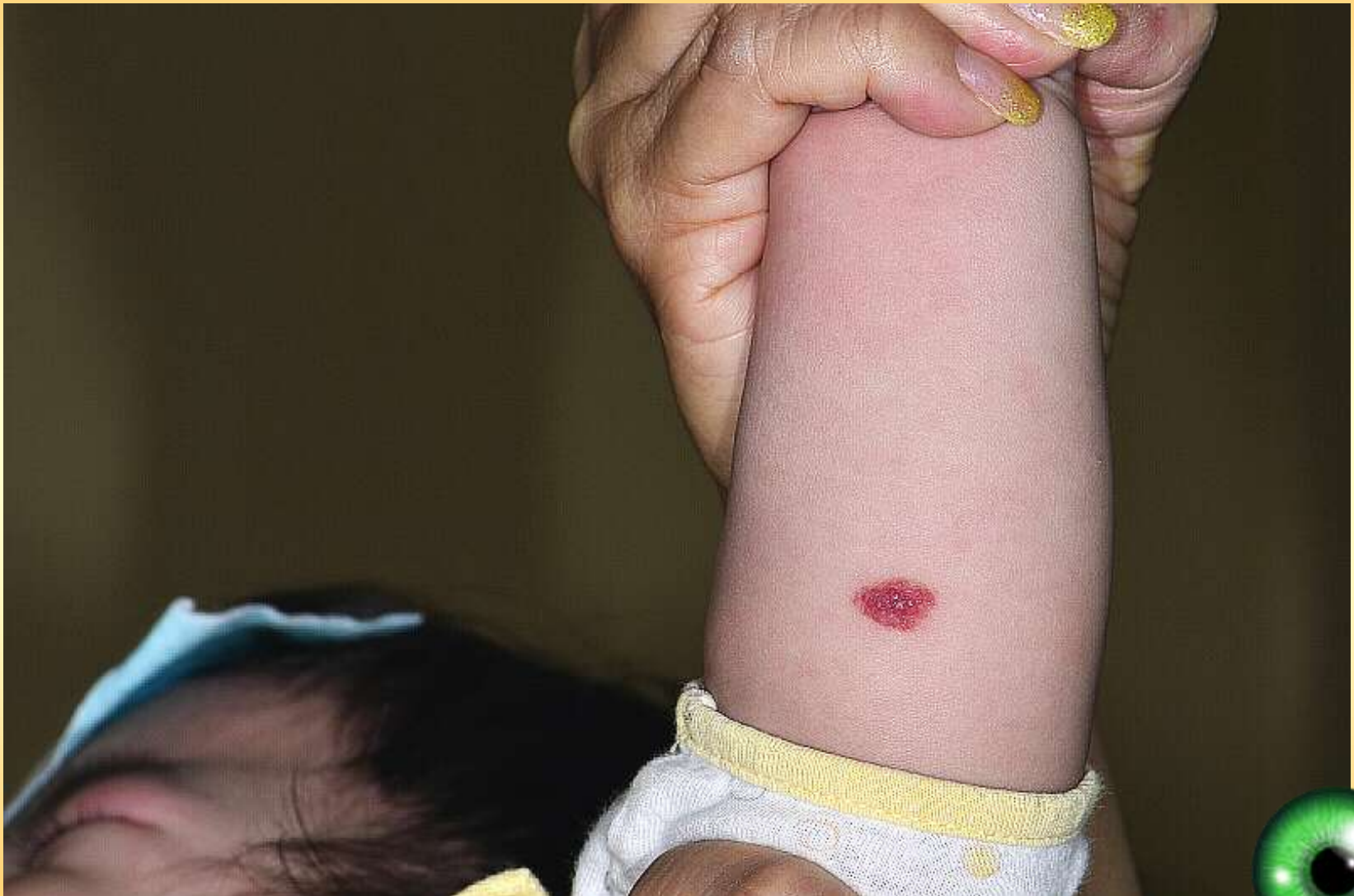?



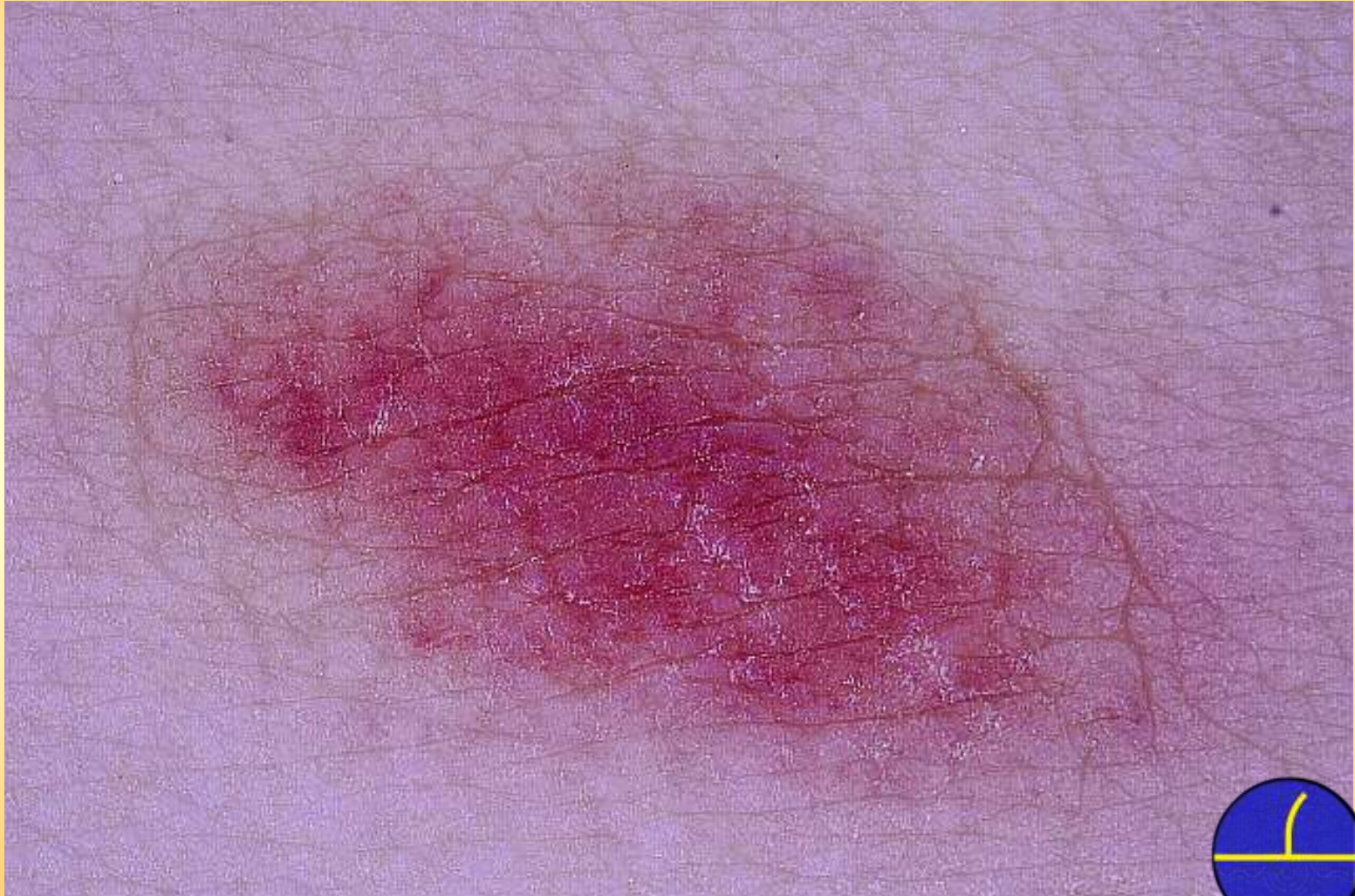Globular naevus



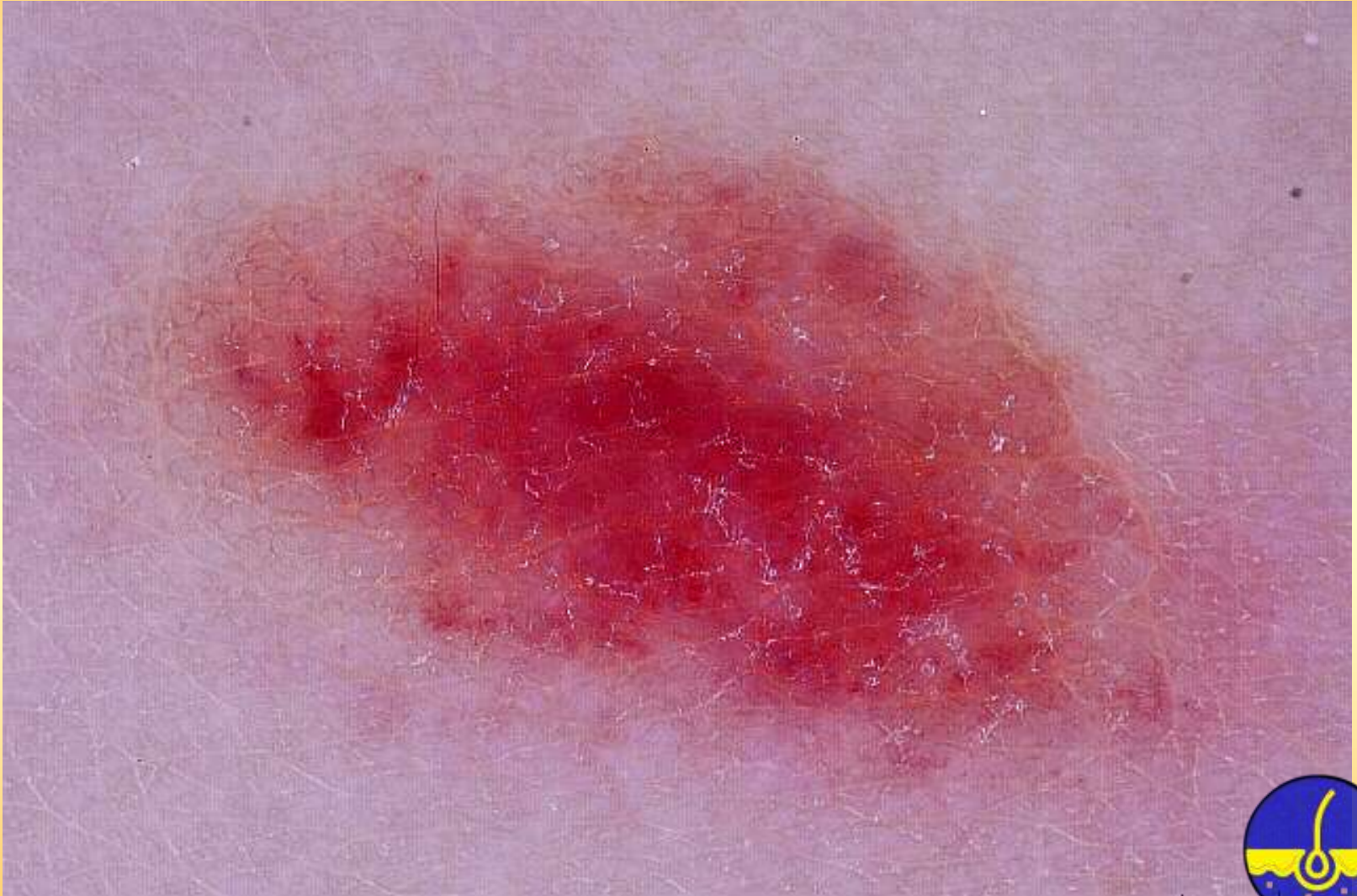Quiz – dermoscopy



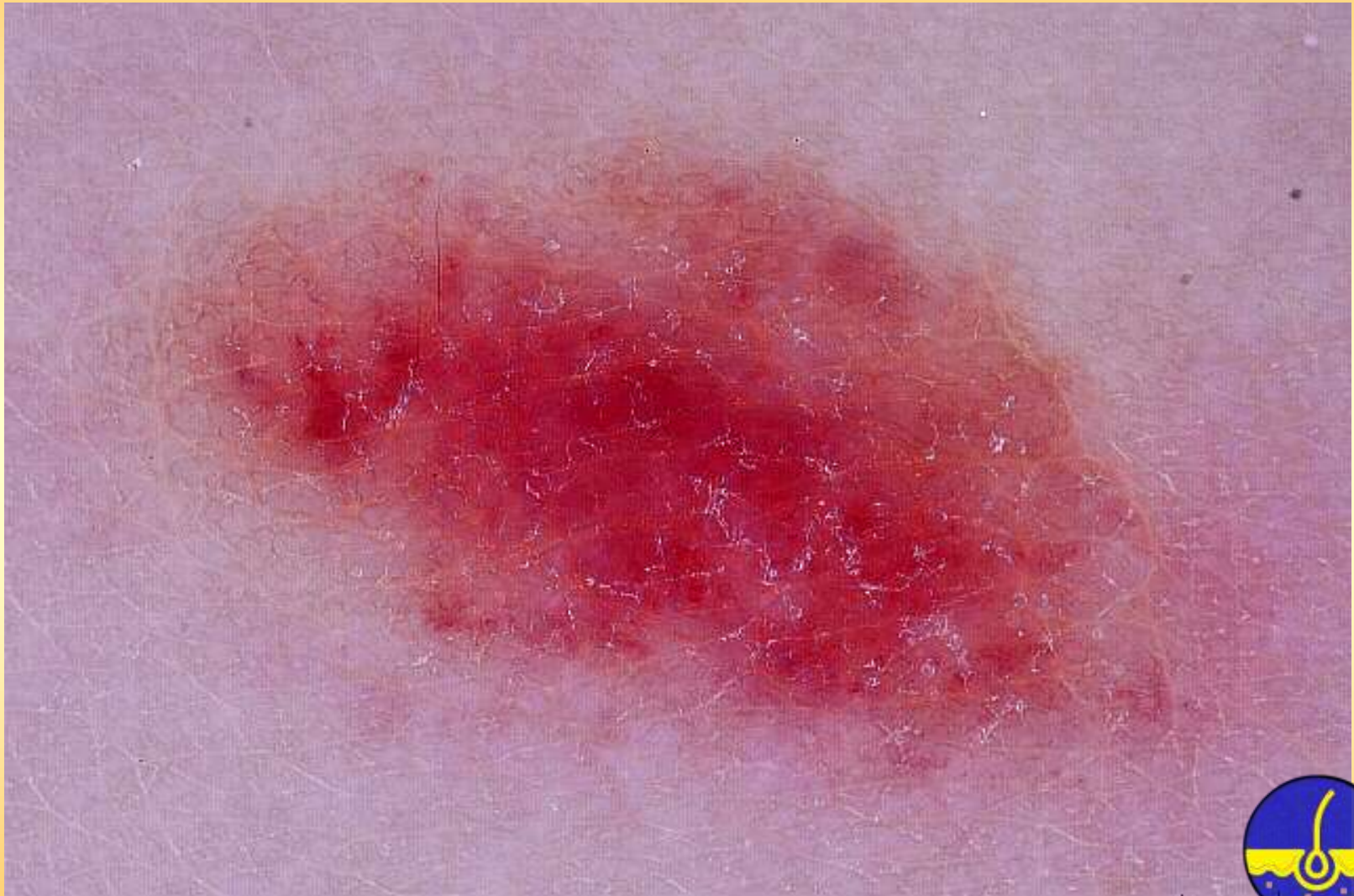Quiz – dermoscopy



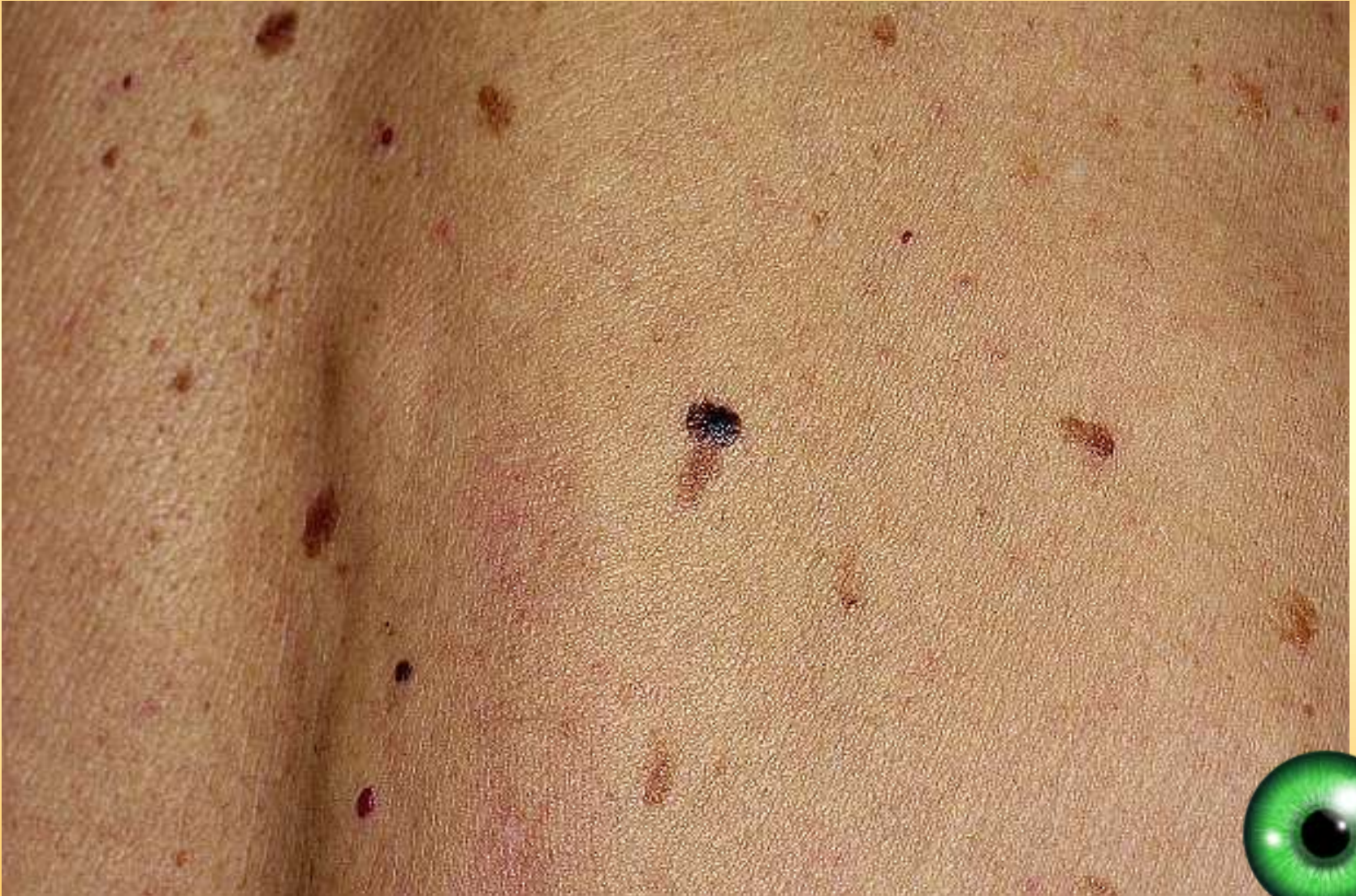?



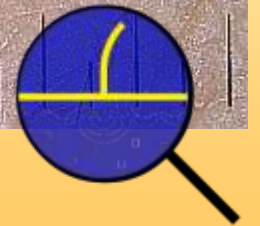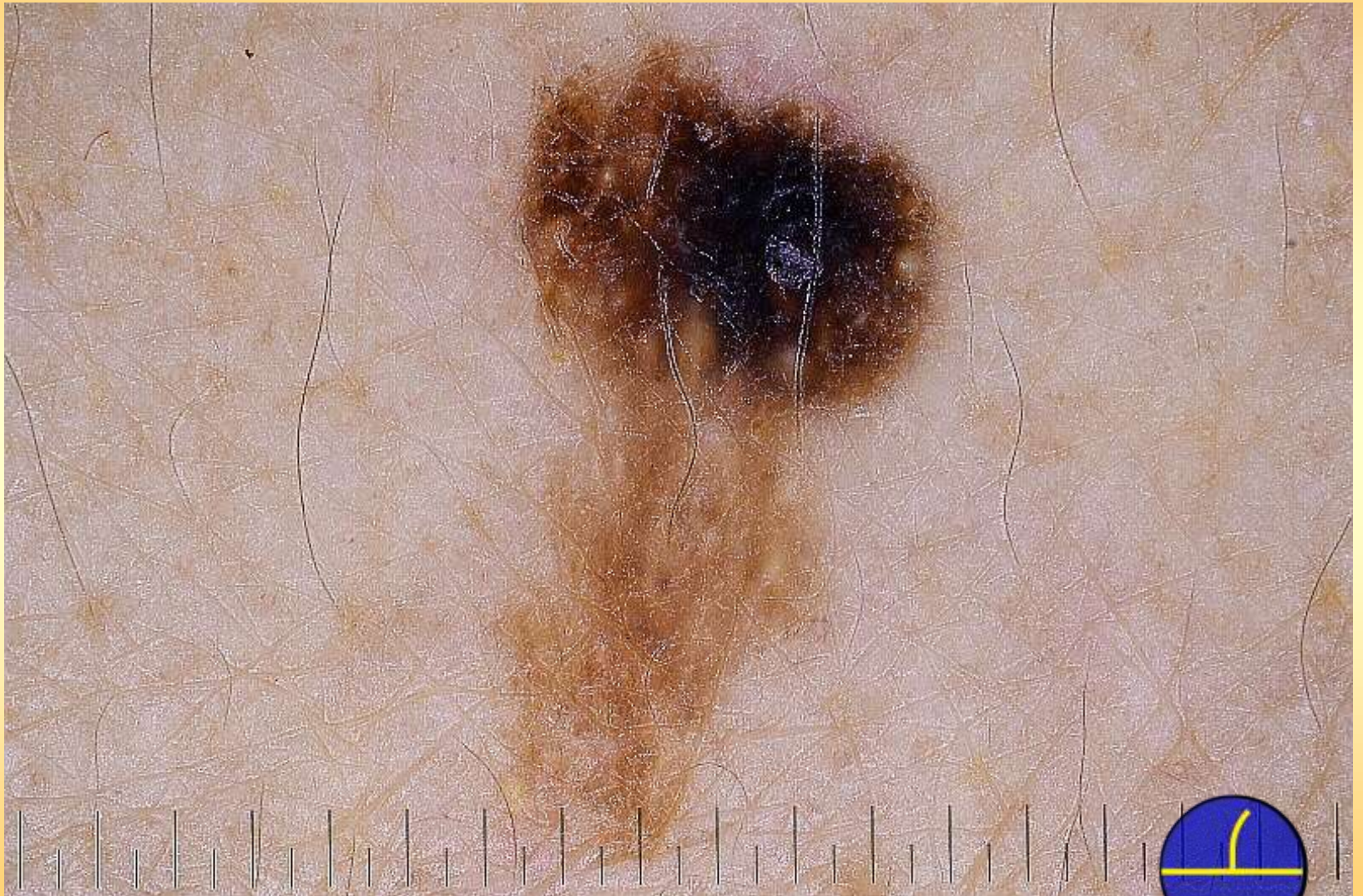Cherry haemangioma



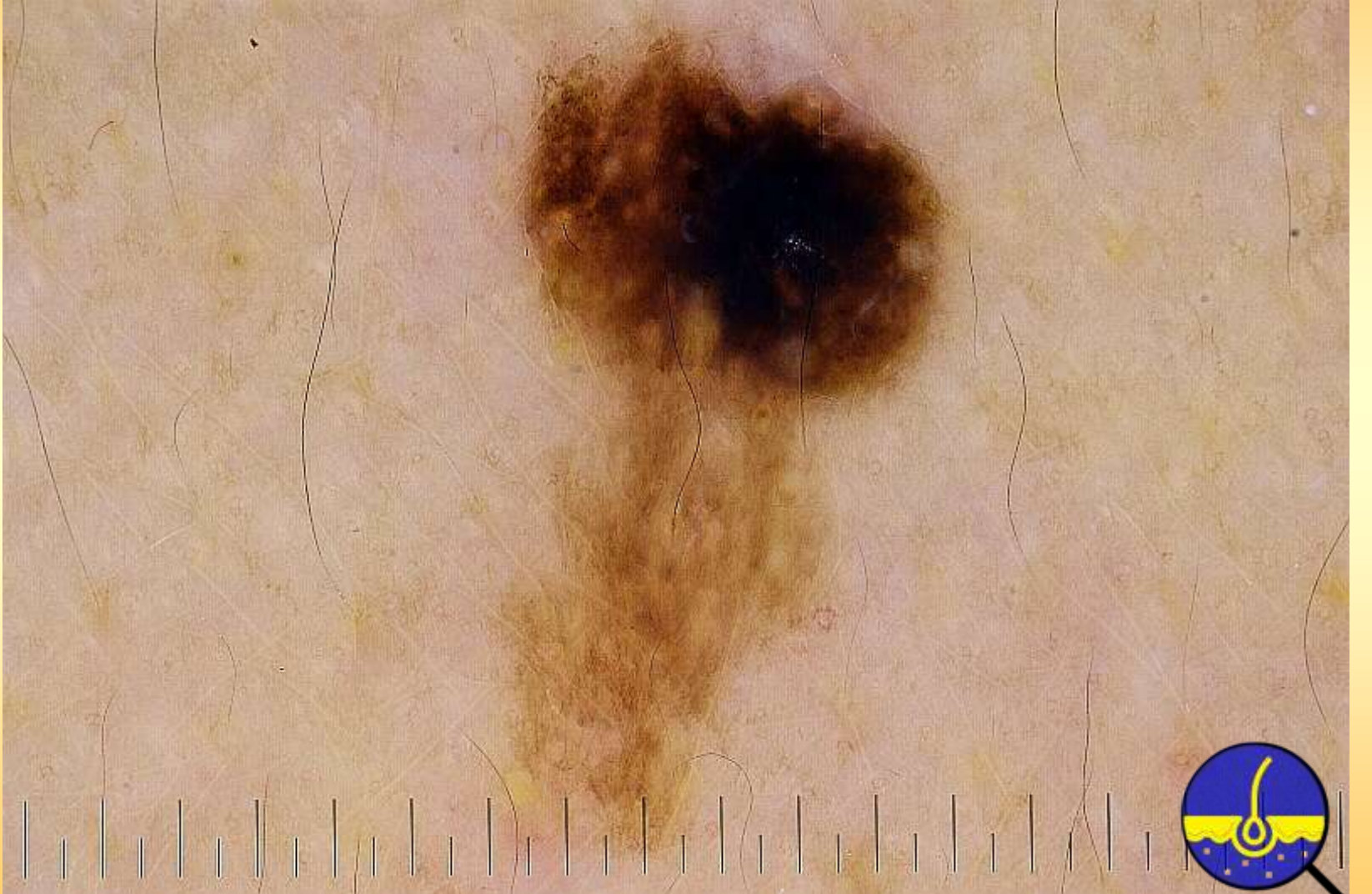
Quiz – dermoscopy



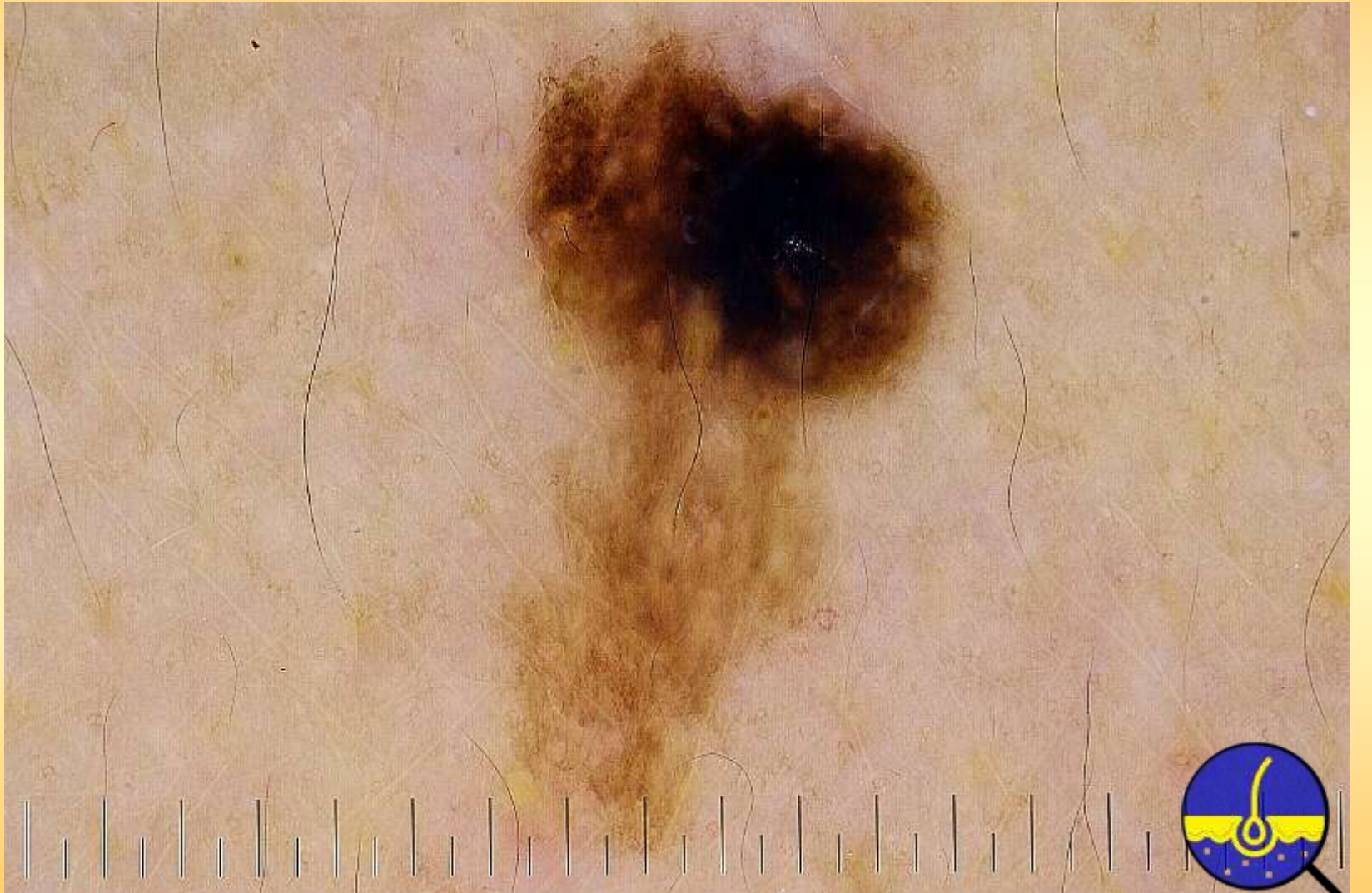
Quiz – dermoscopy



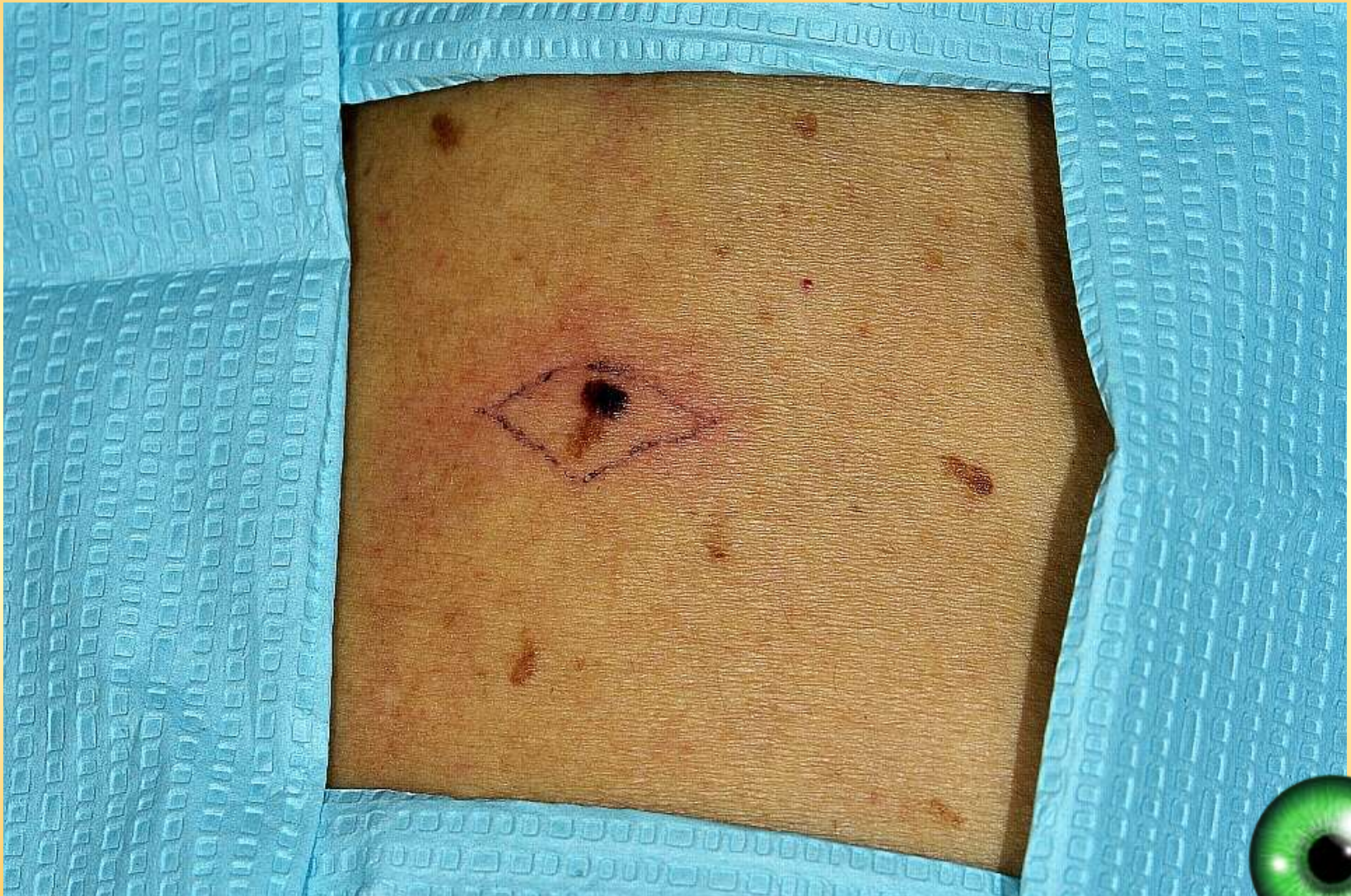?



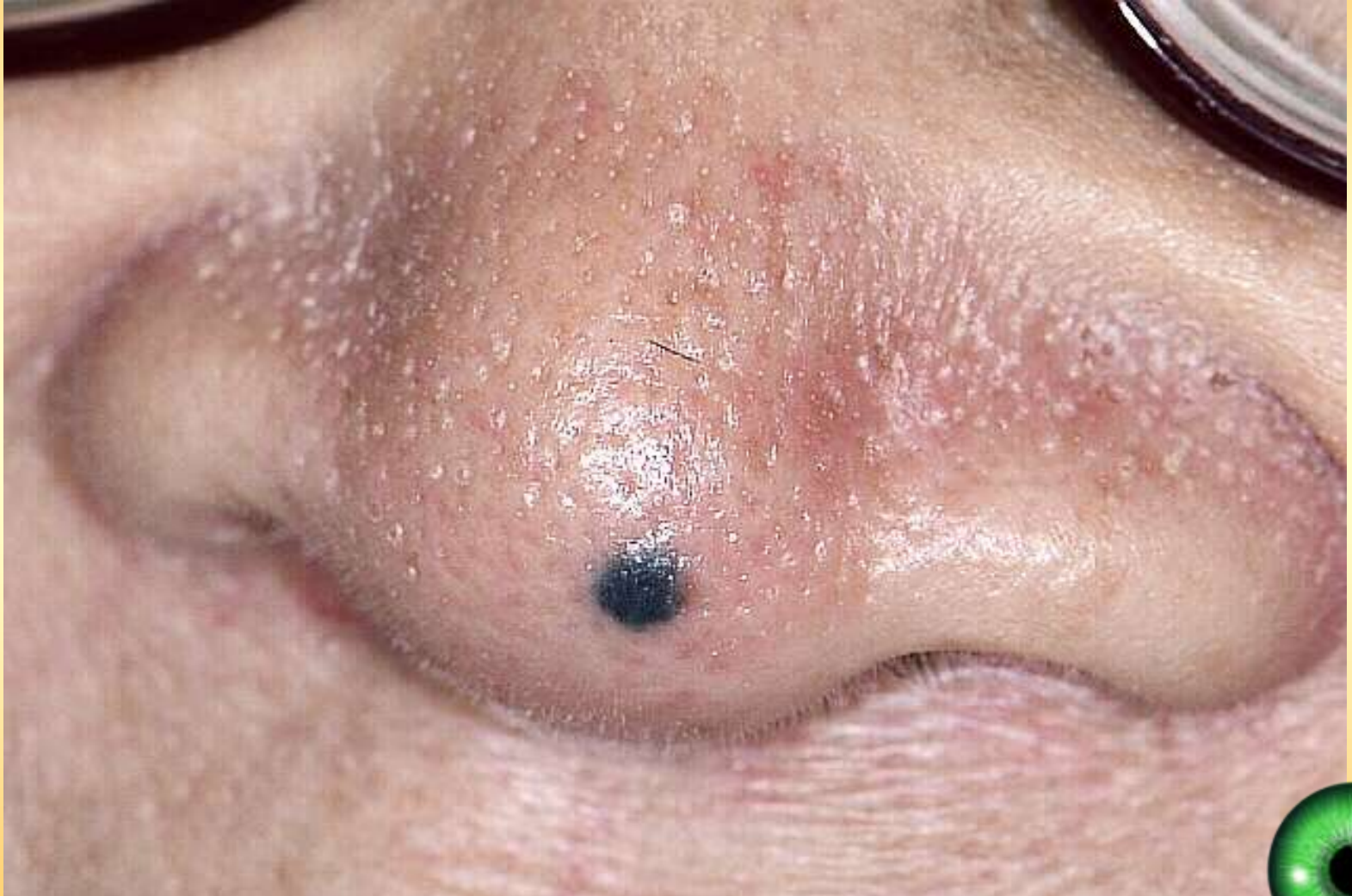Atypical melanocytic naevus



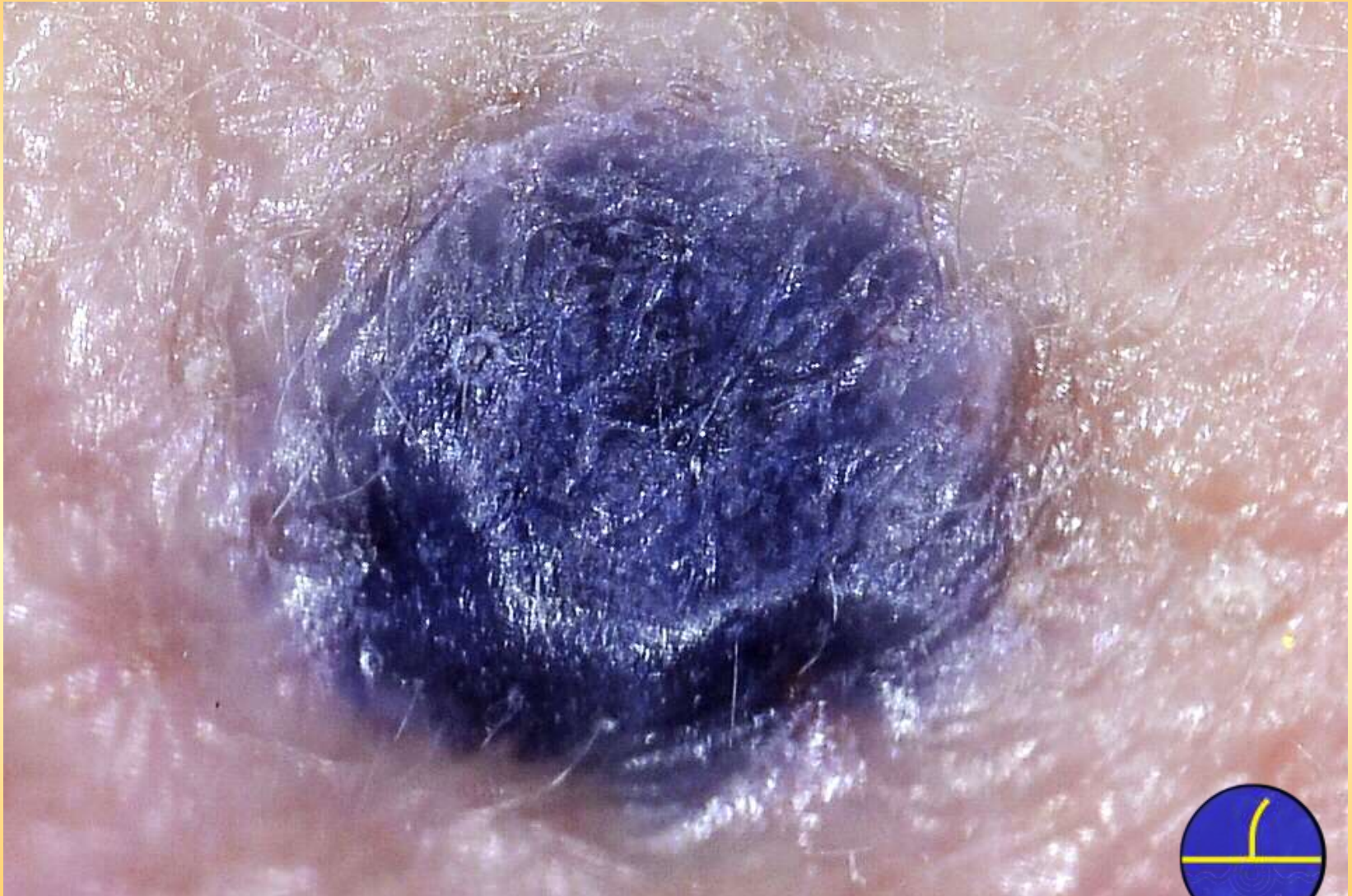Quiz – dermoscopy



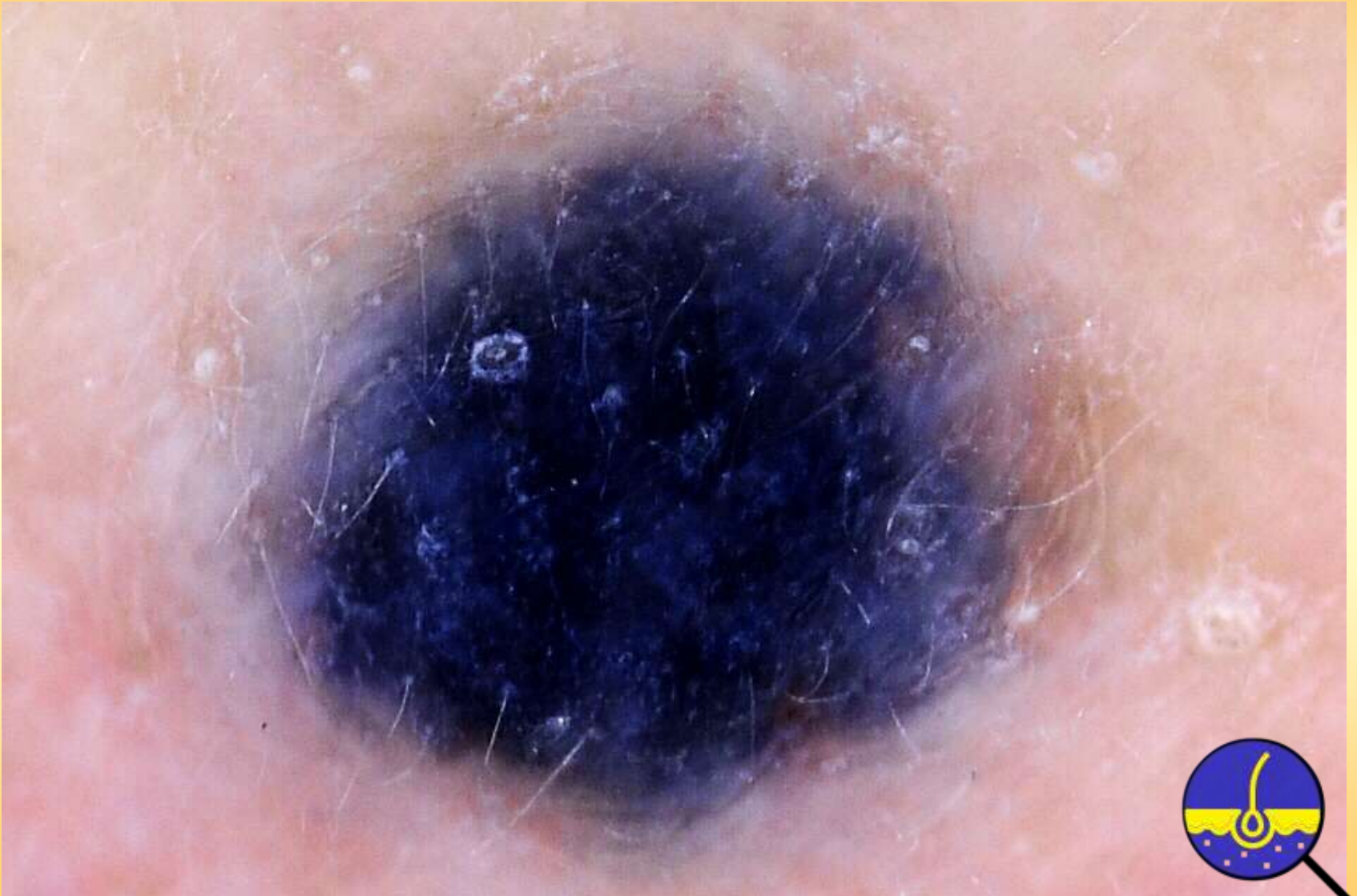Quiz – dermoscopy



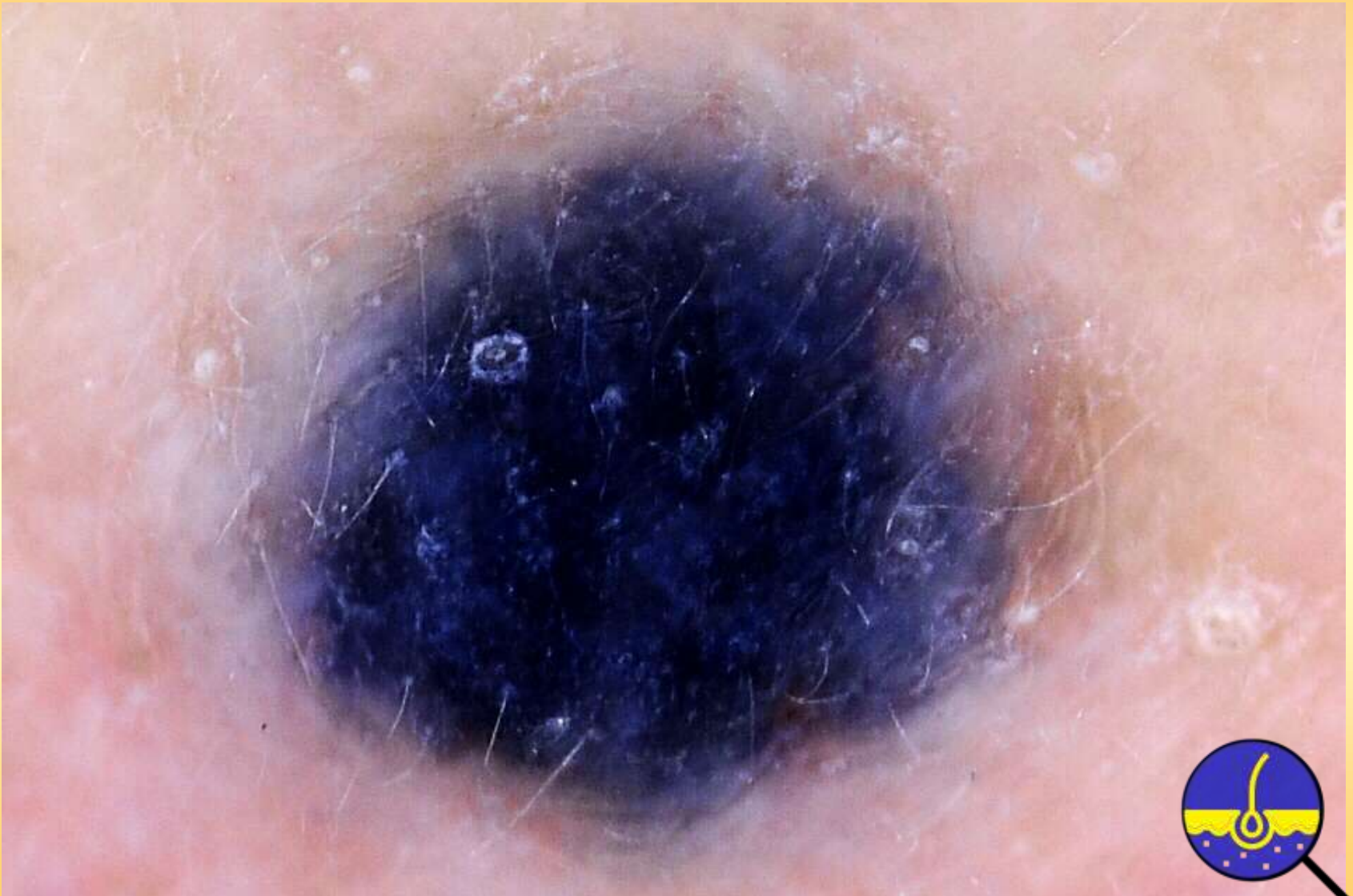Quiz – dermoscopy



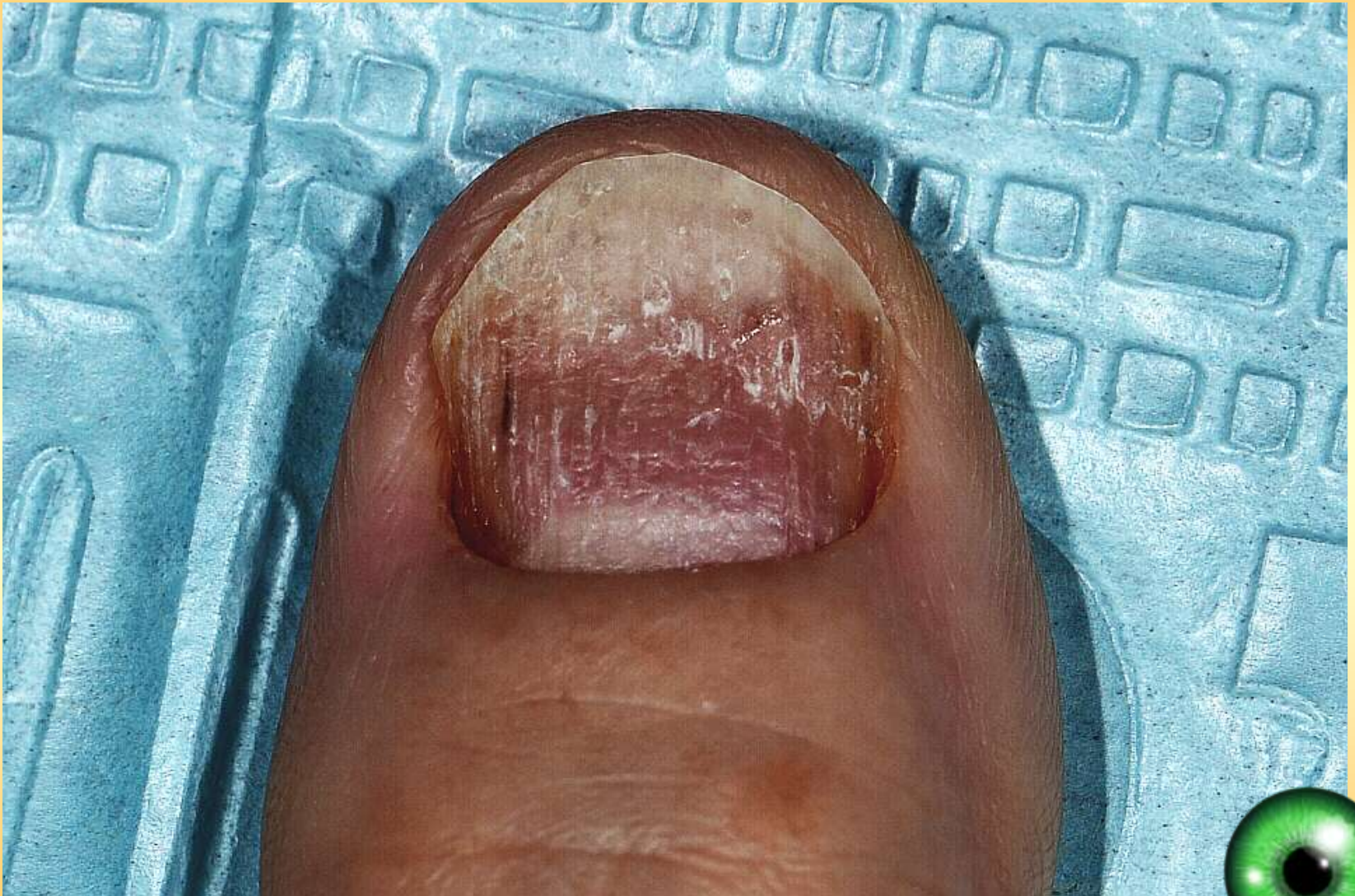?



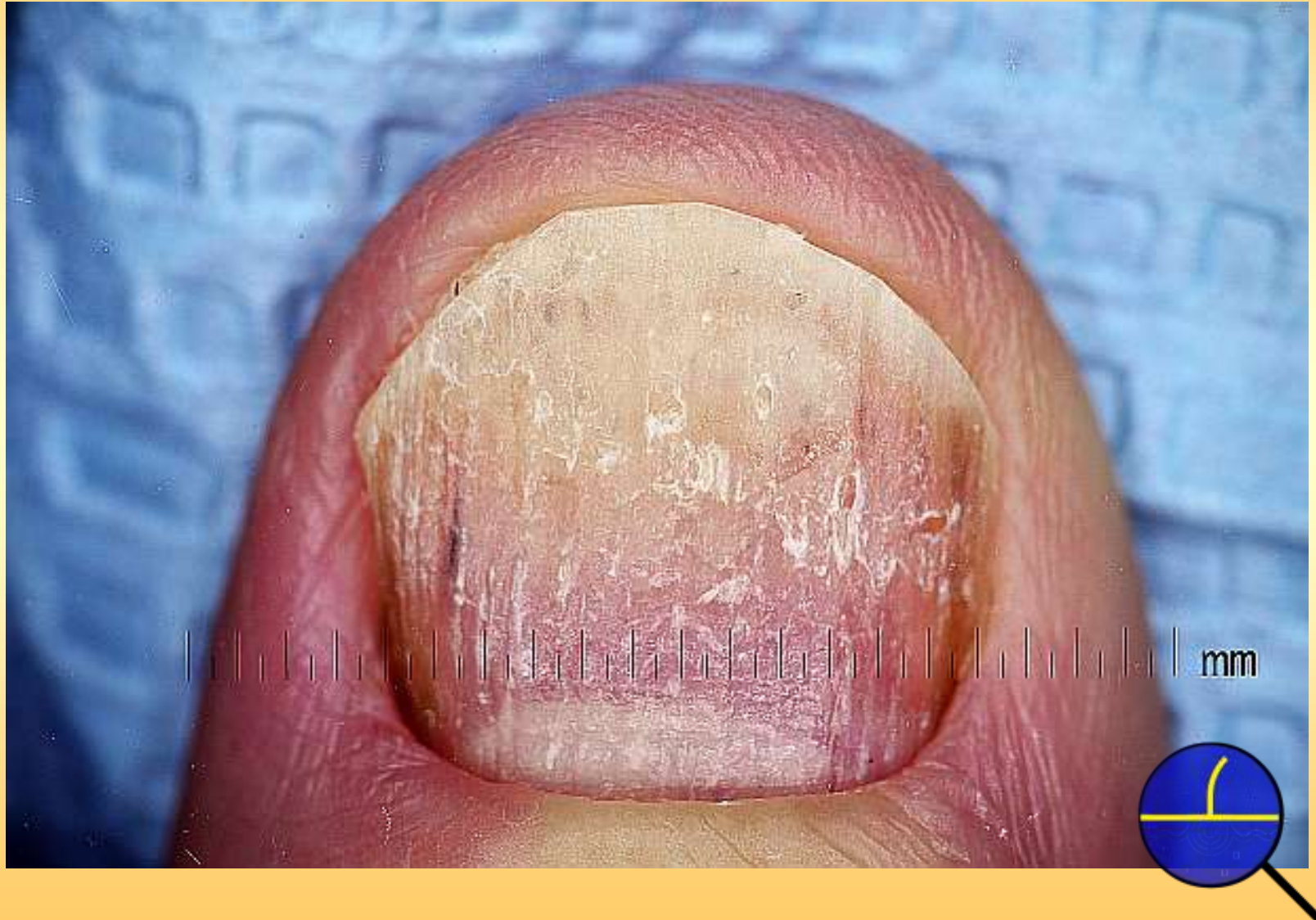Blue naevus – Blue variety



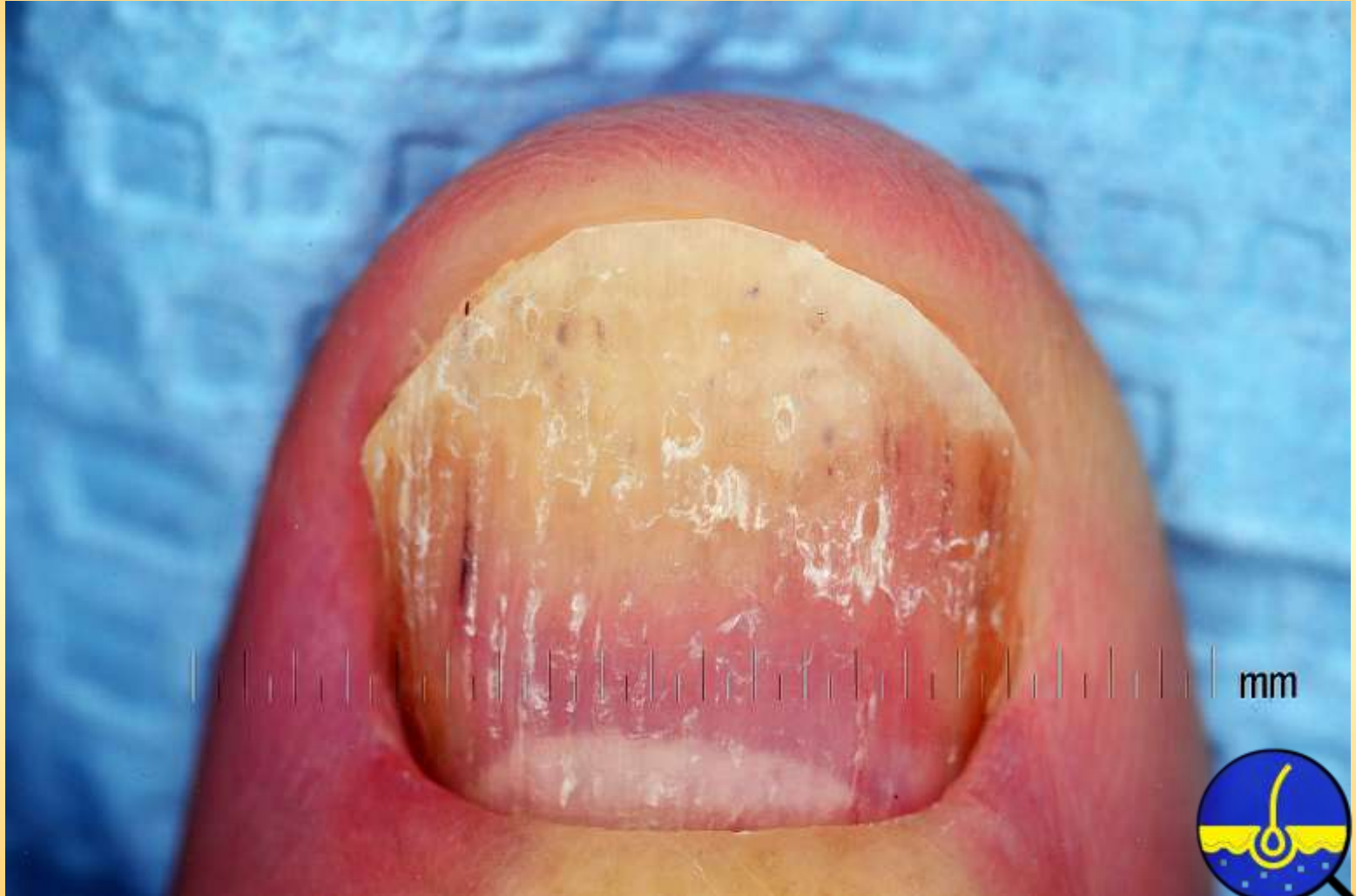Quiz – dermoscopy



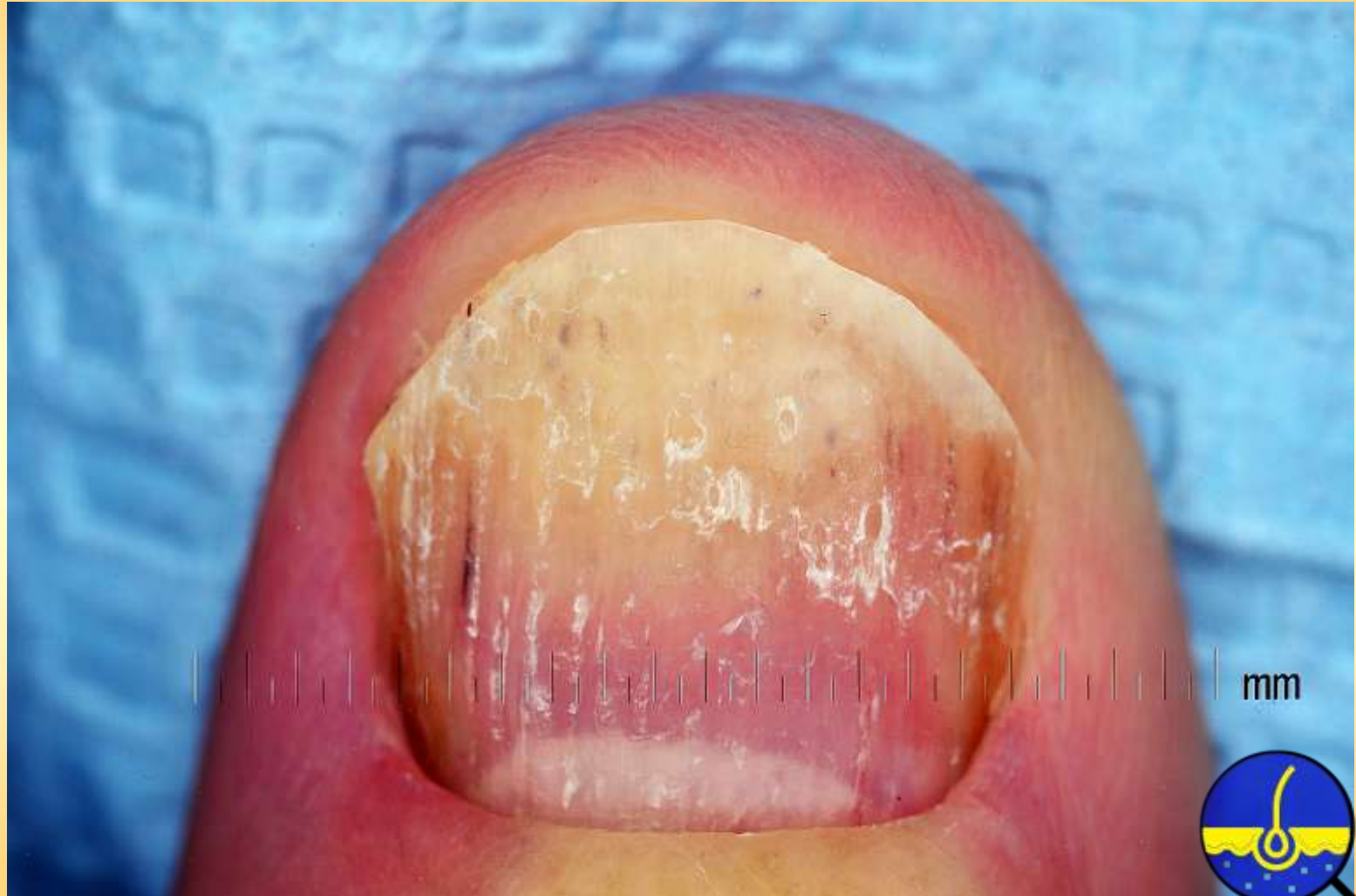Quiz – dermoscopy



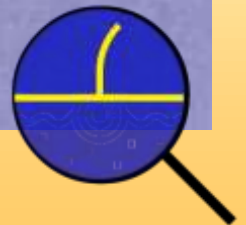?



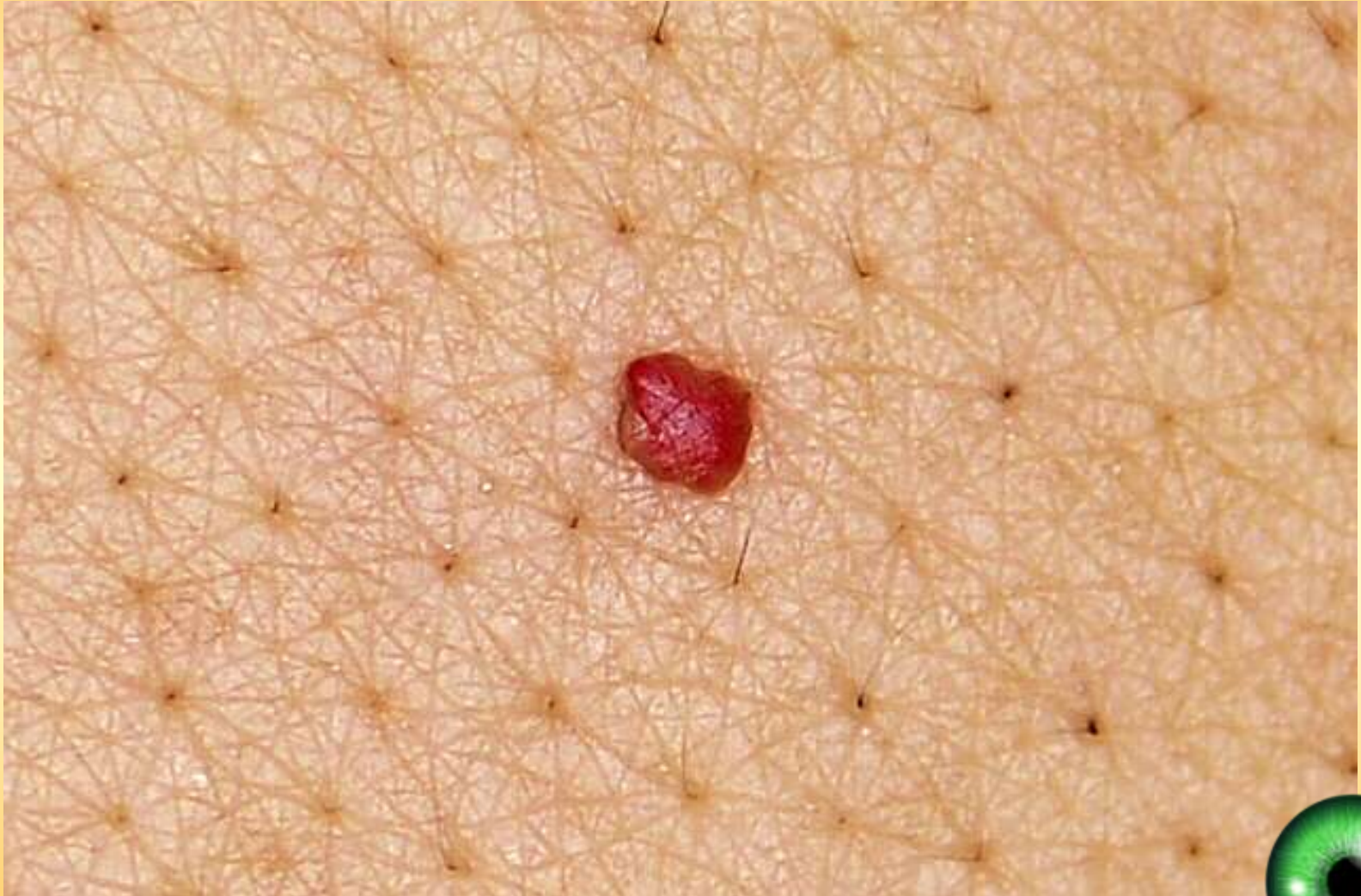Pitting



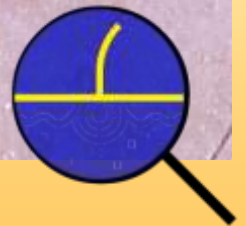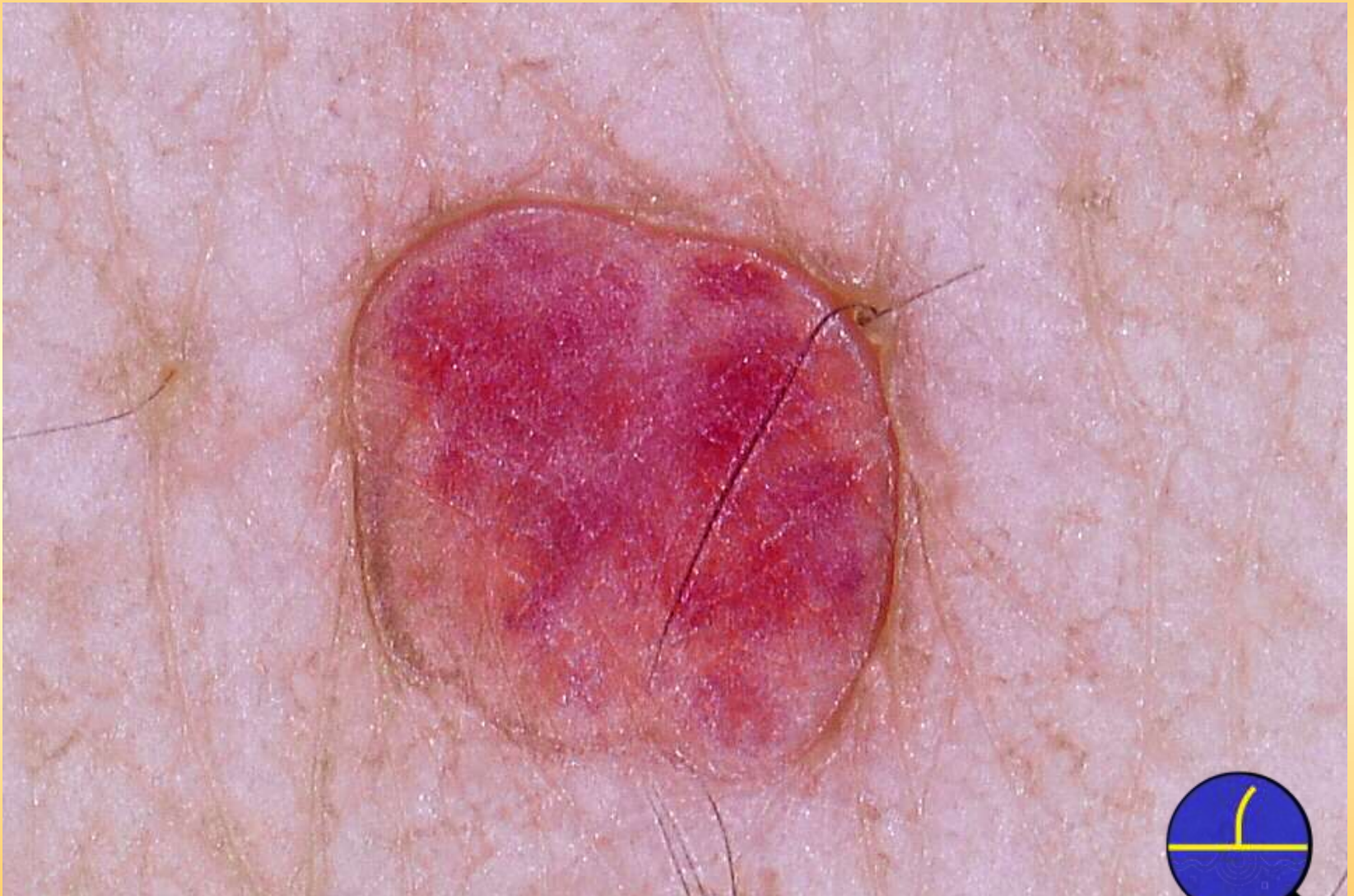
Quiz – dermoscopy



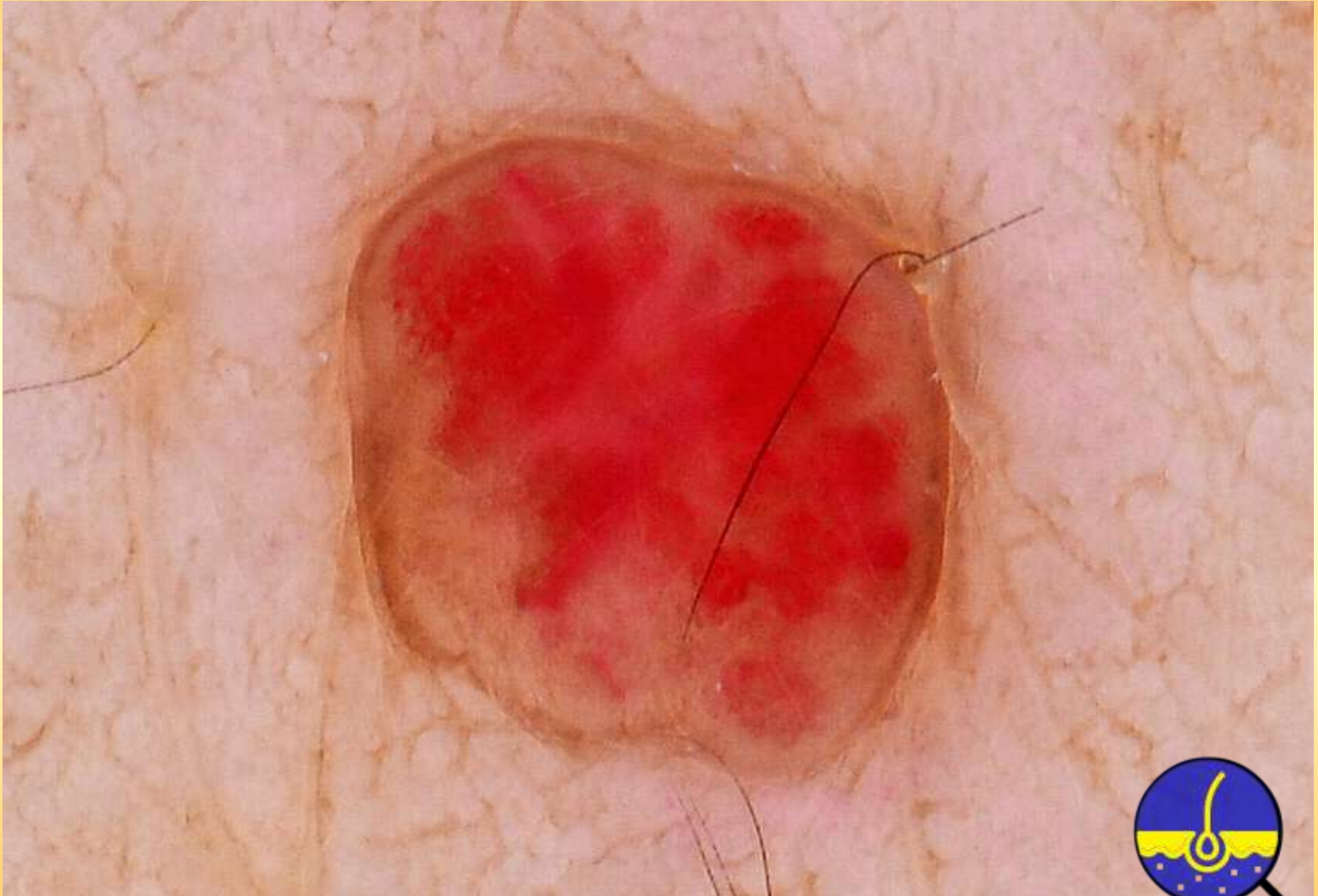
Quiz – dermoscopy



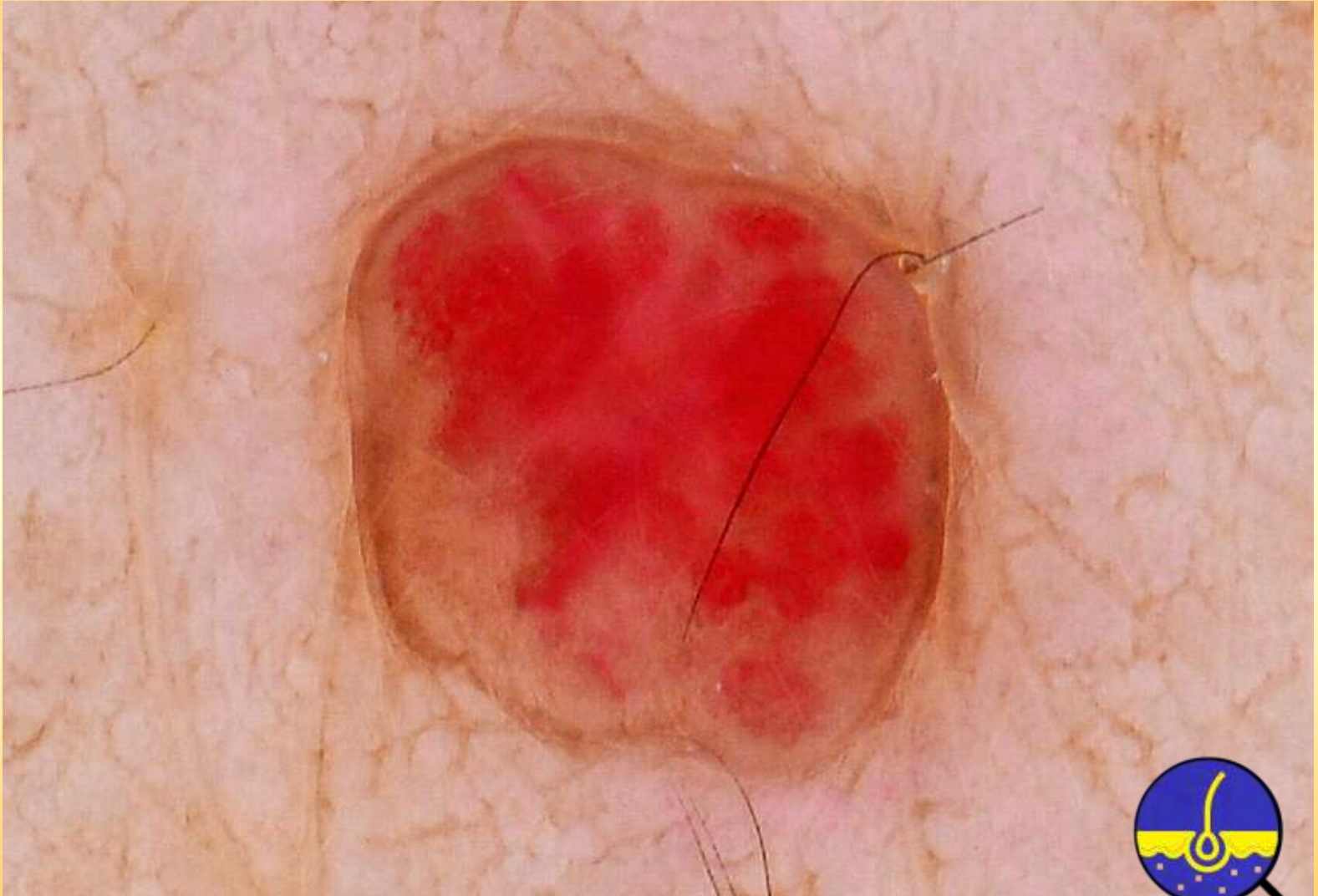
Quiz – dermoscopy



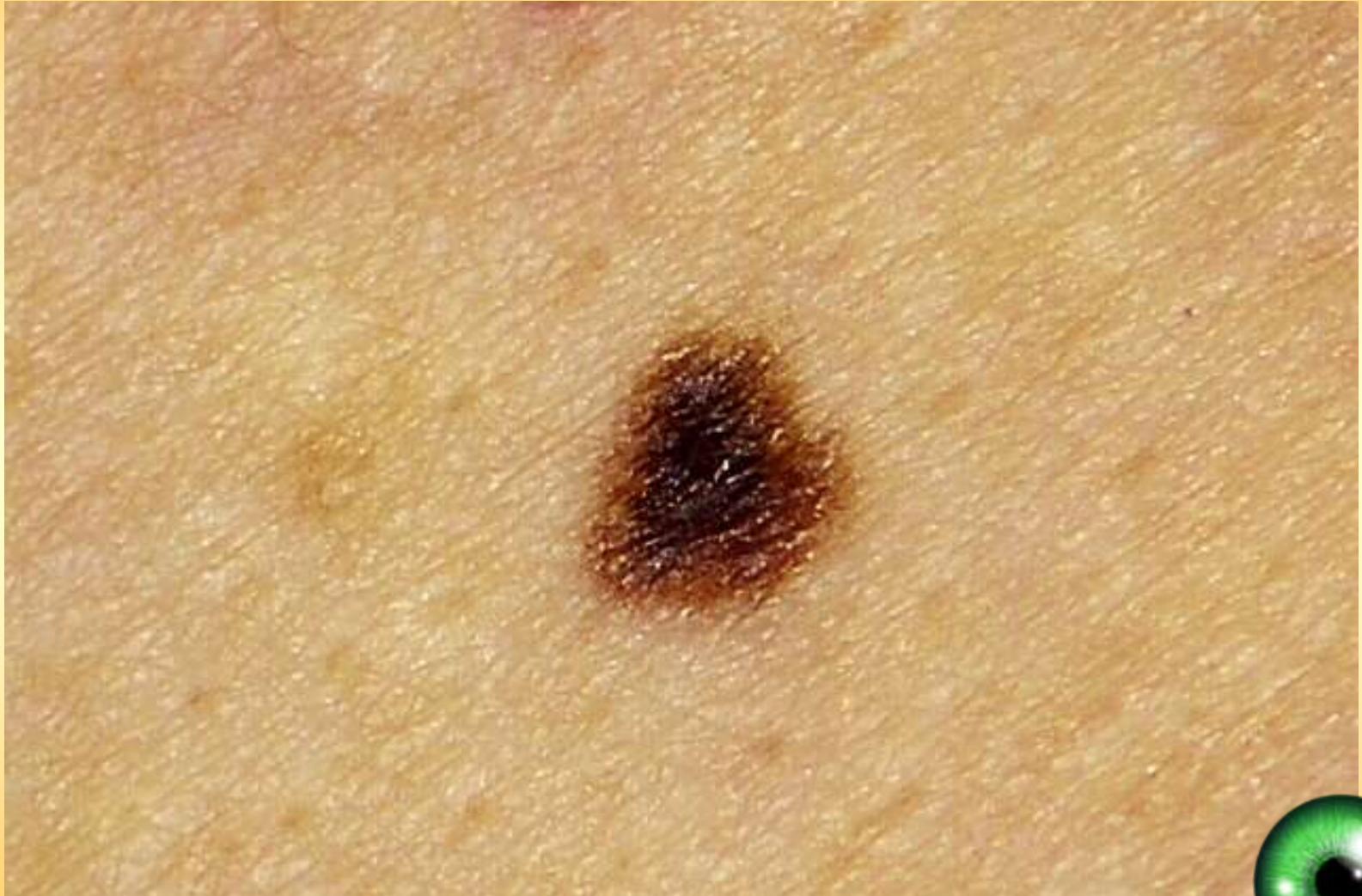?



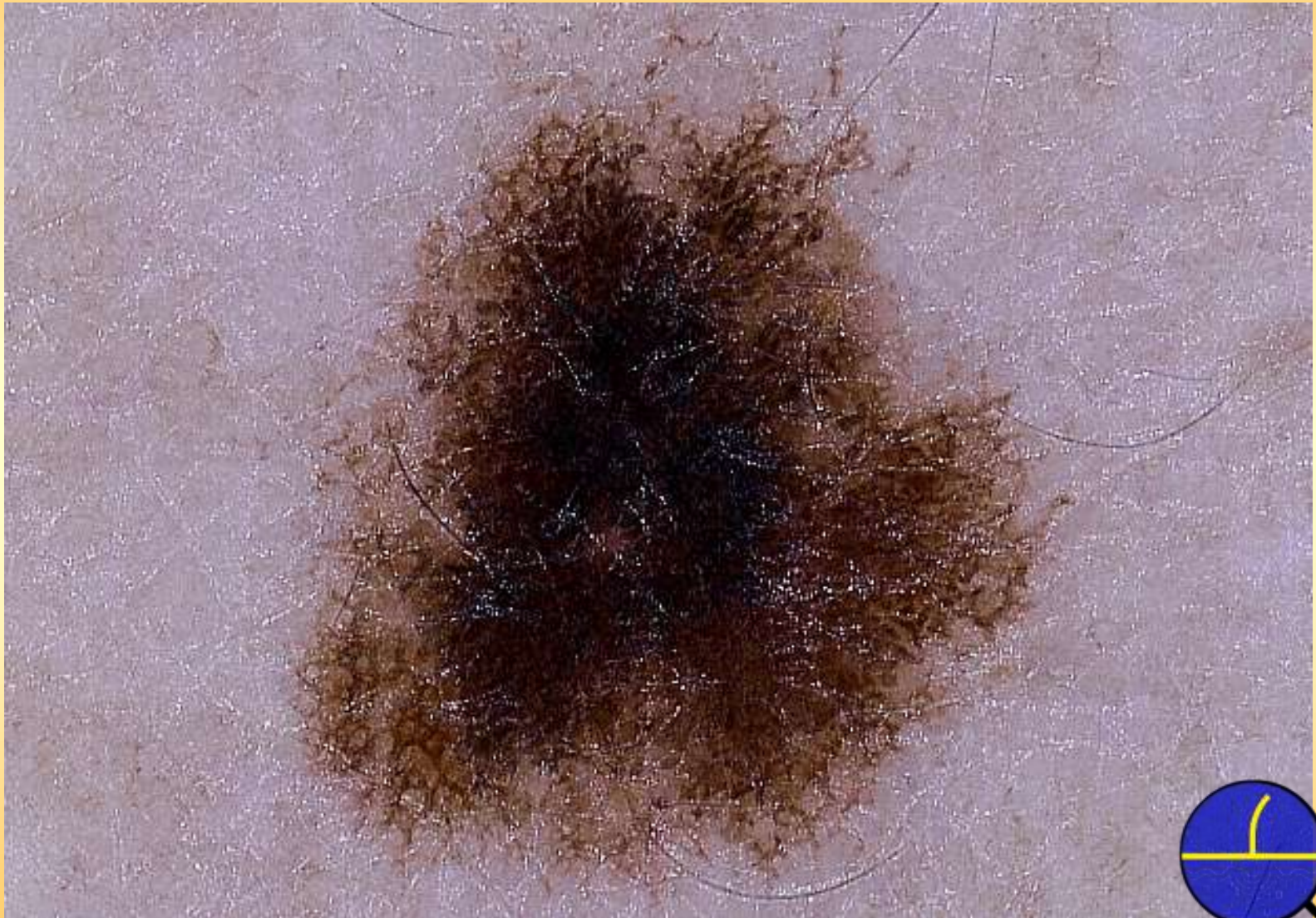Cherry haemangioma



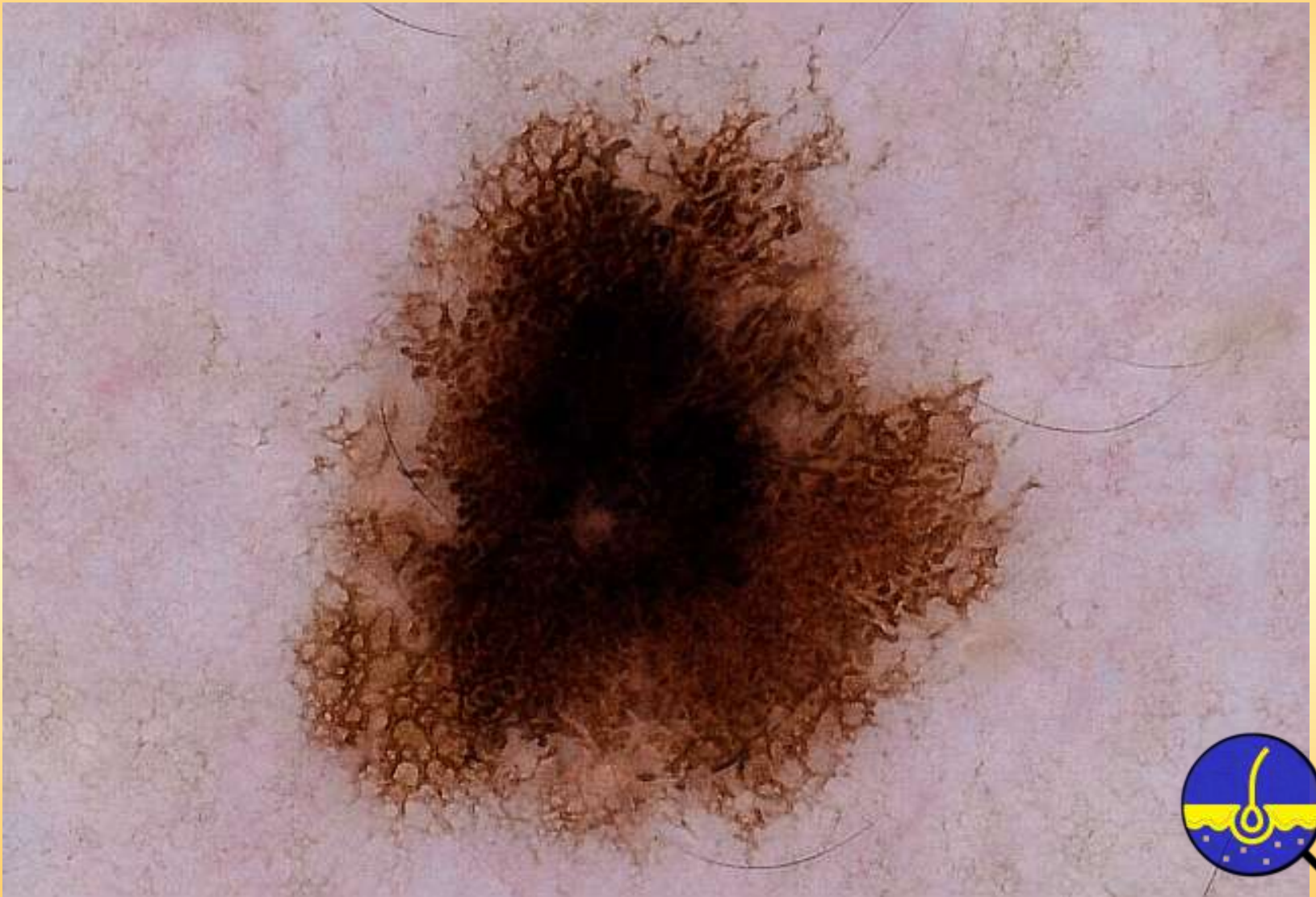
Quiz – dermoscopy



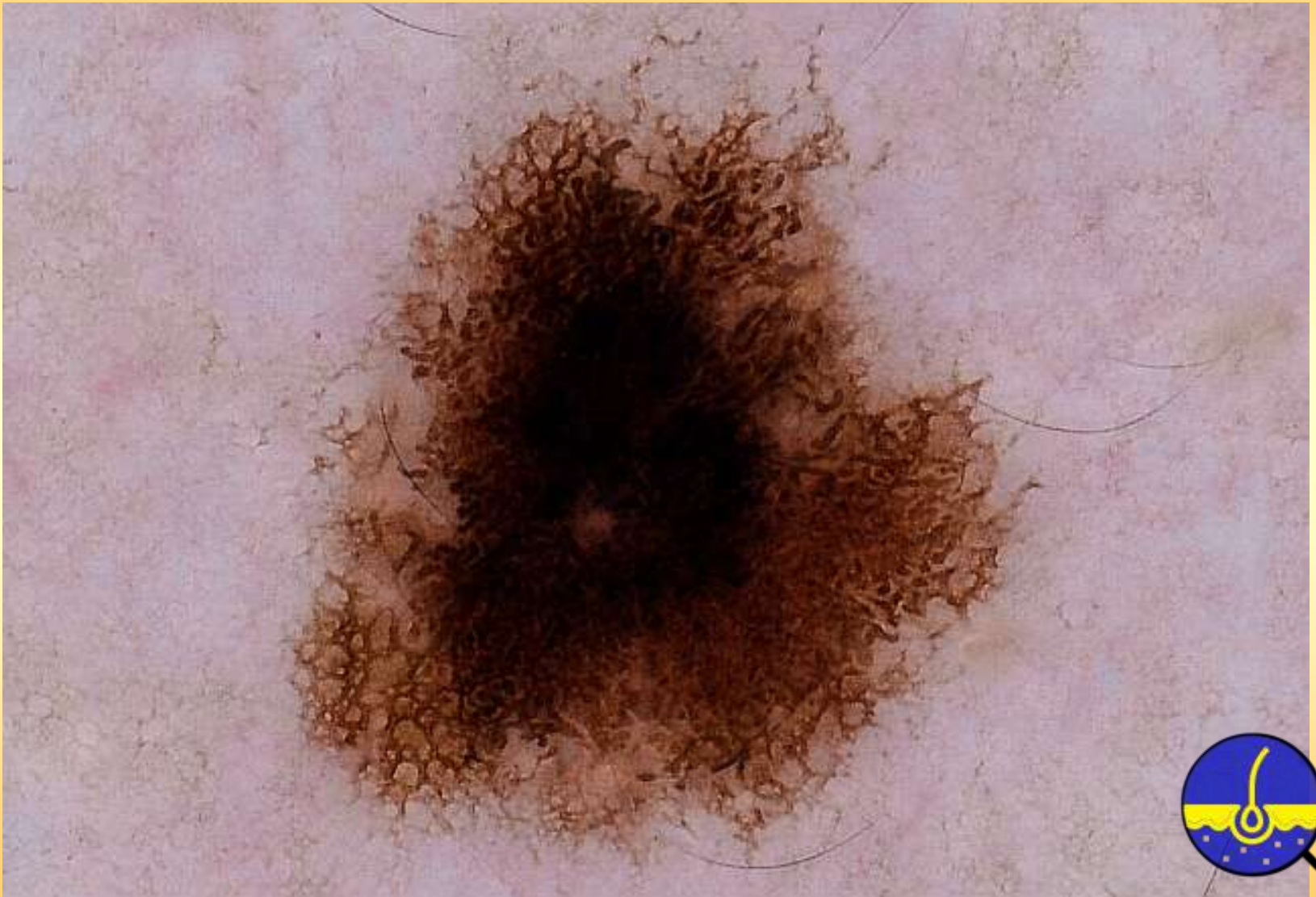
Quiz – dermoscopy



?

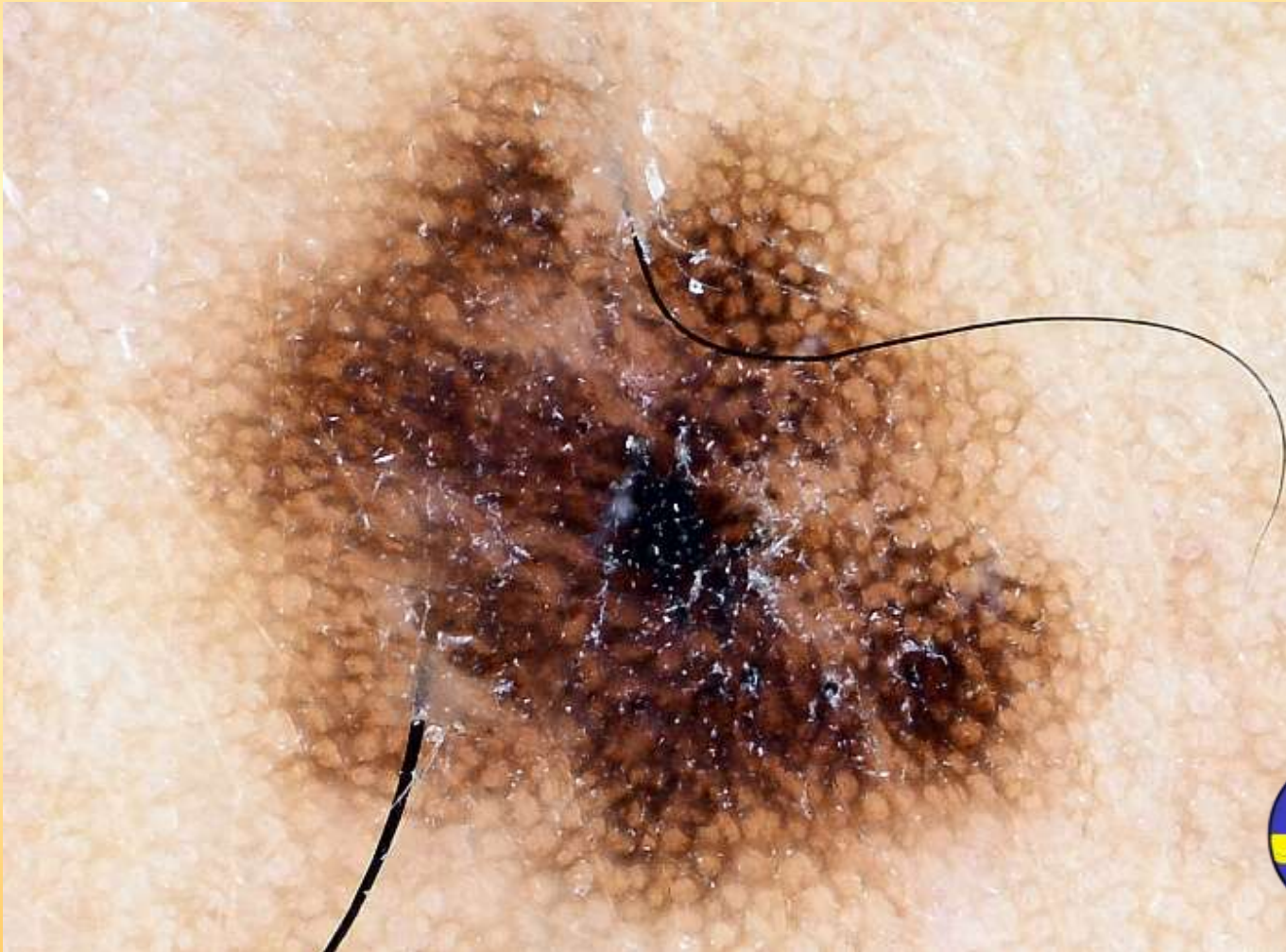

Ink spot lentigo

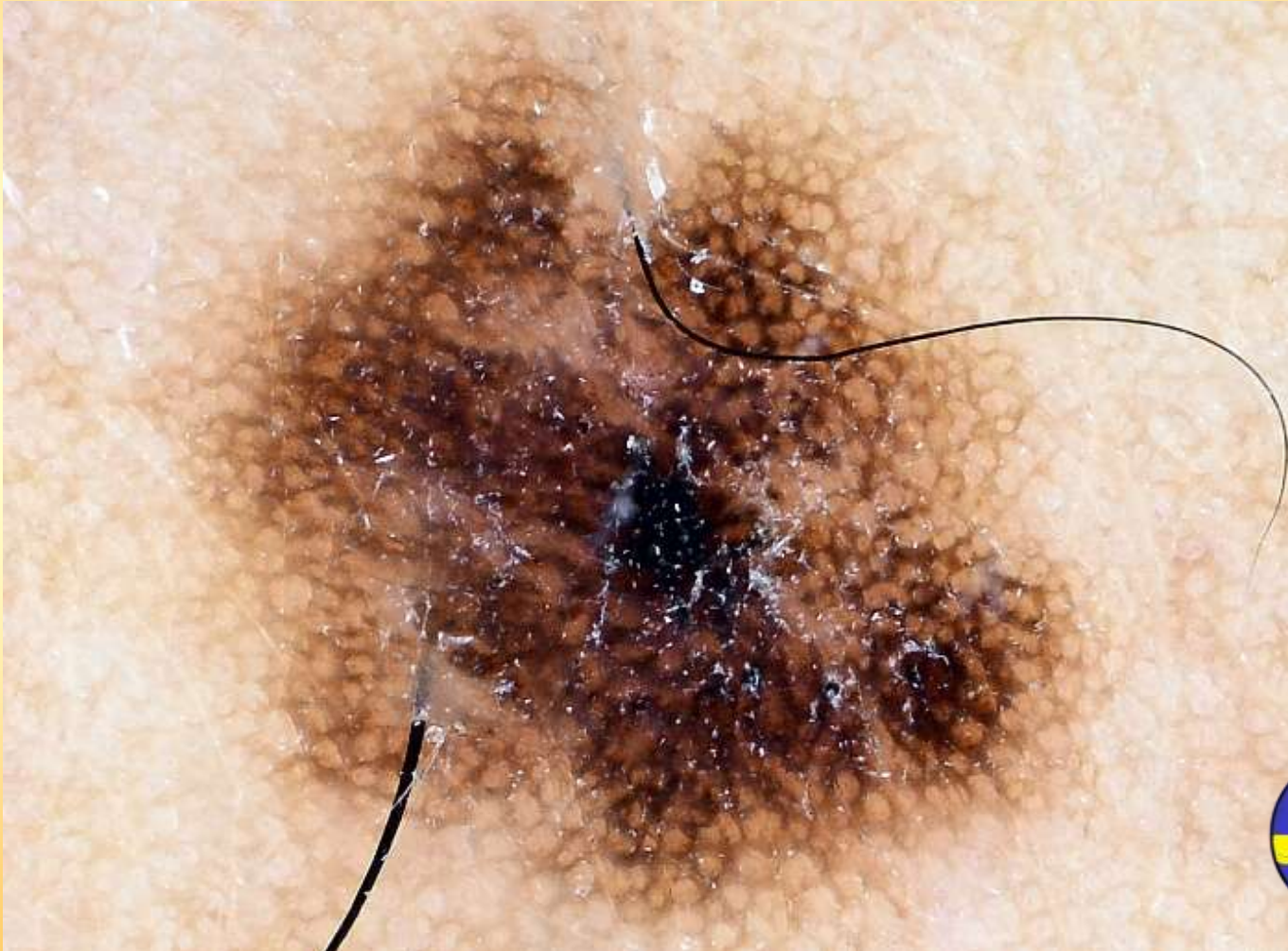

Quiz – dermoscopy

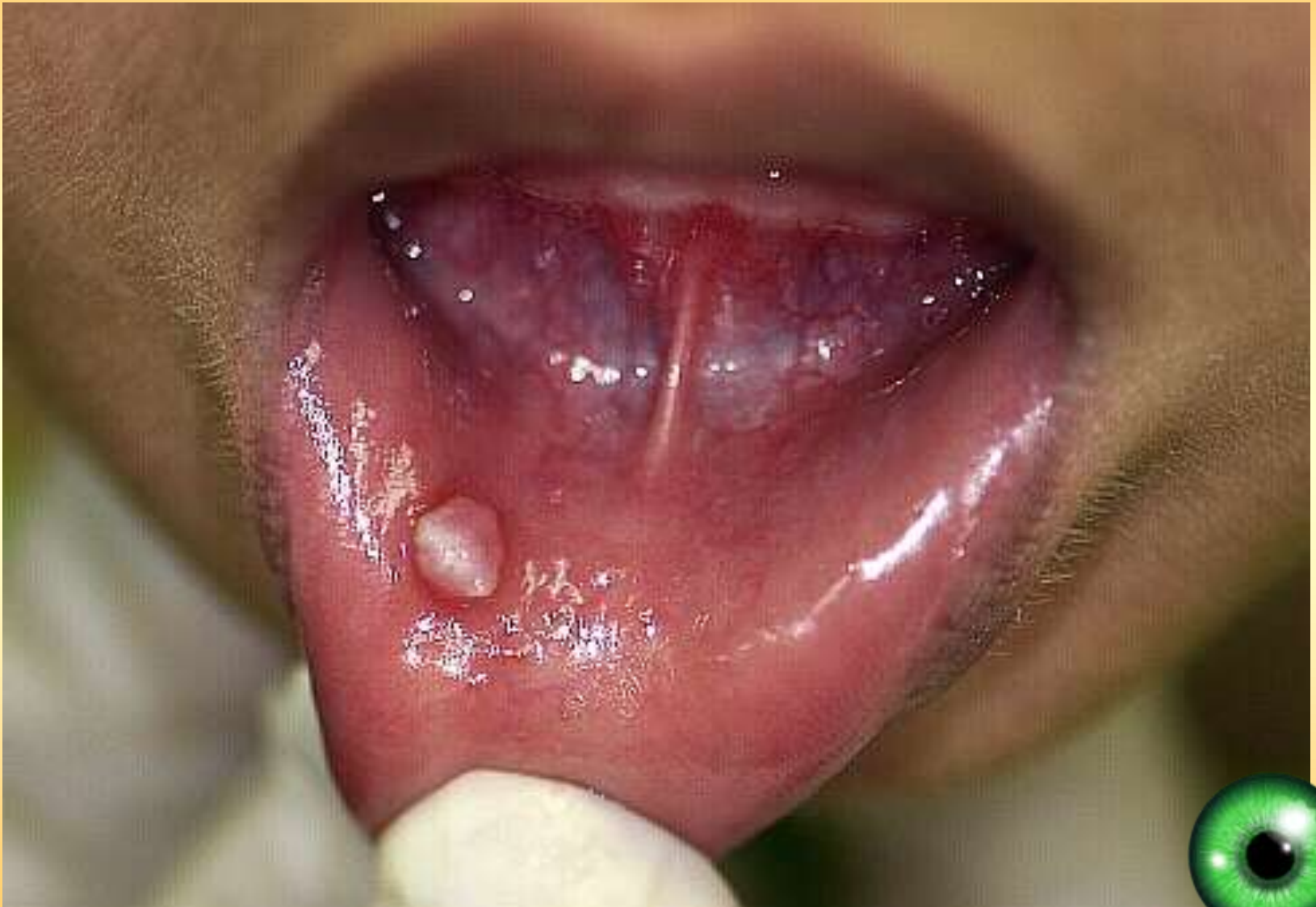What sign is being demonstrated?



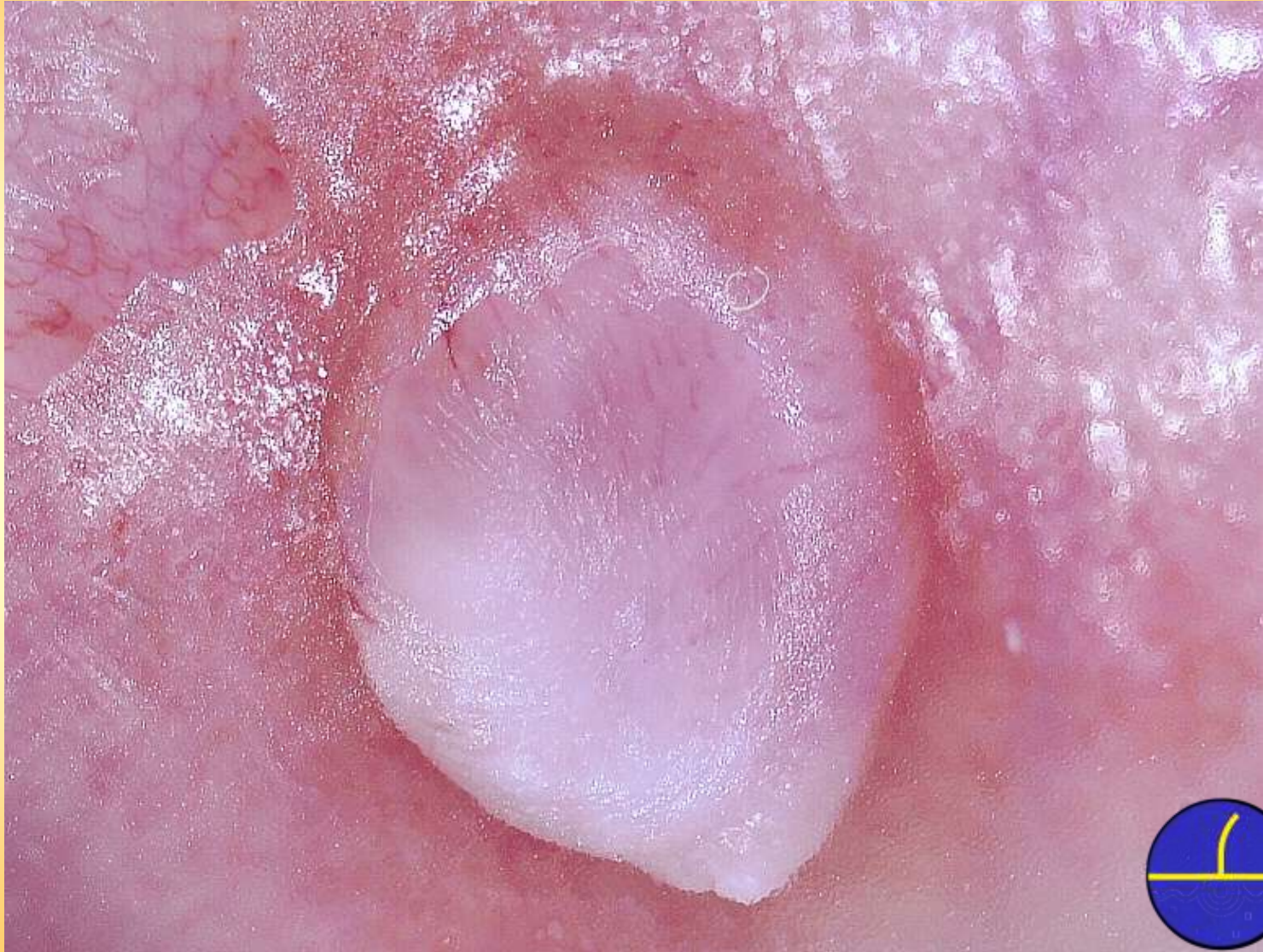Stickiness



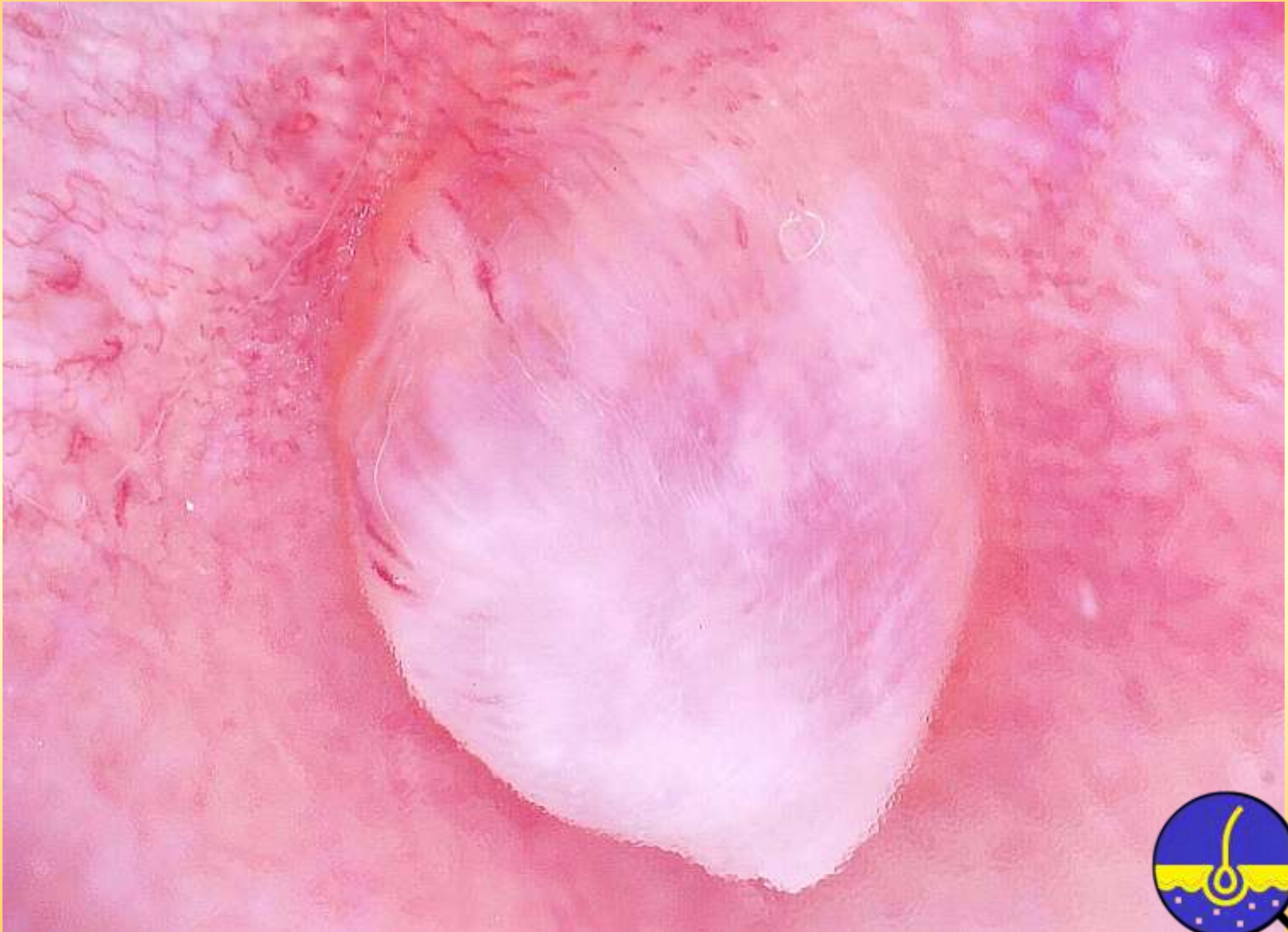Quiz – dermoscopy



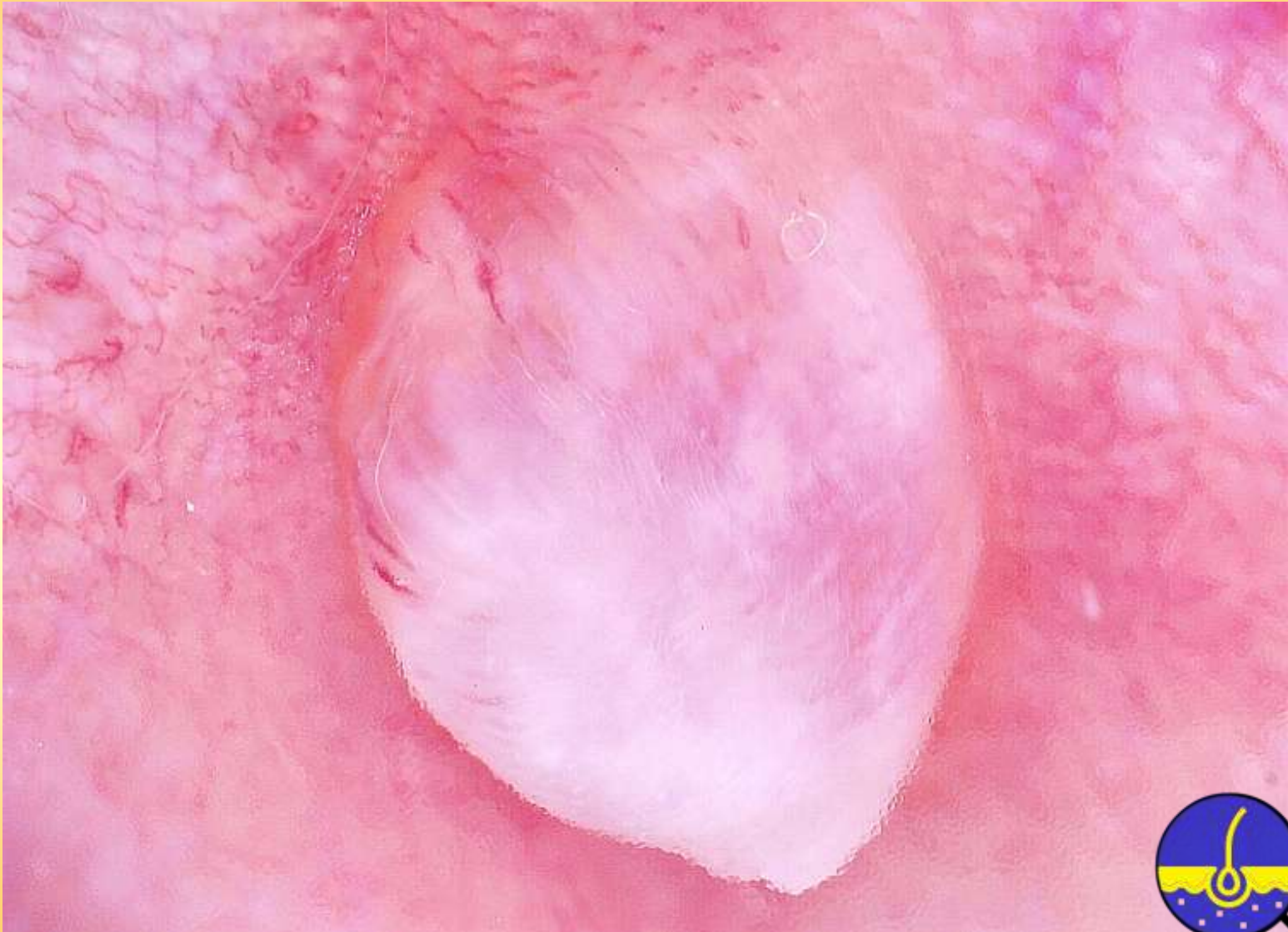Quiz – dermoscopy



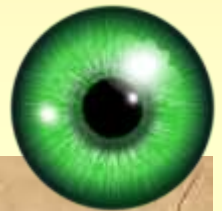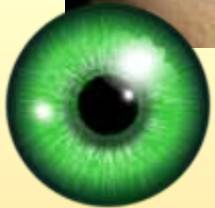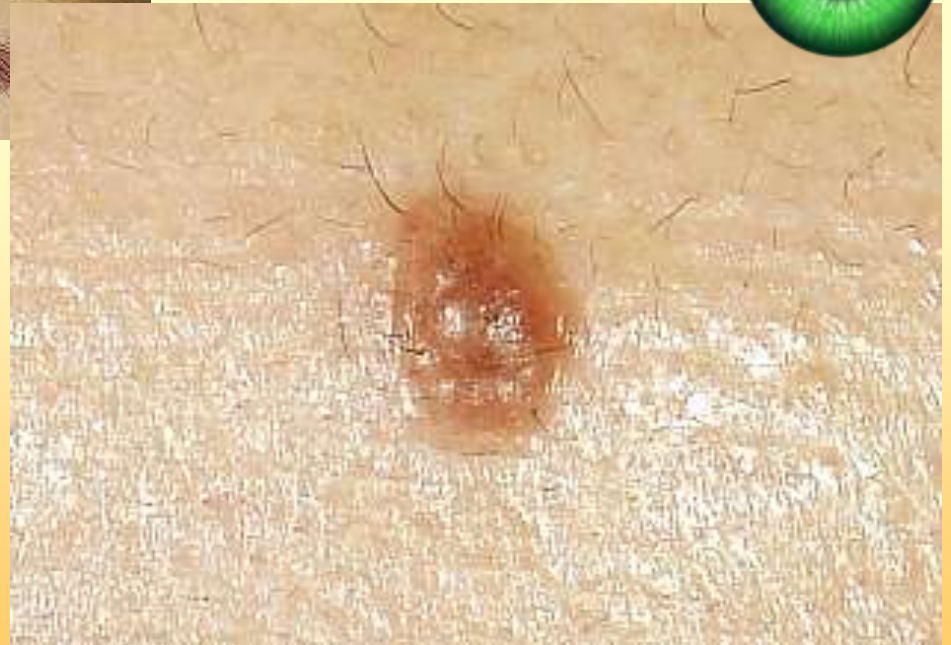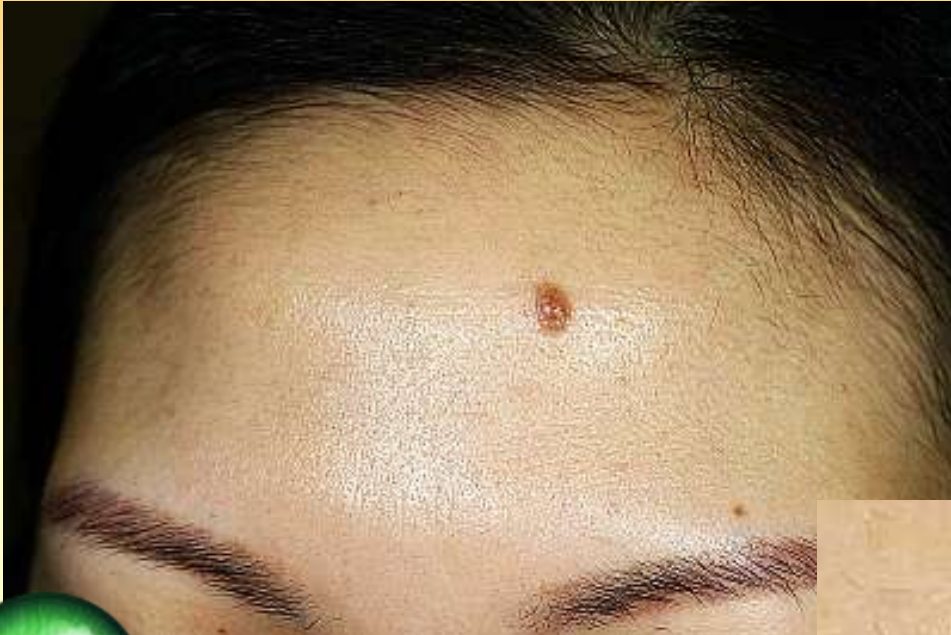?



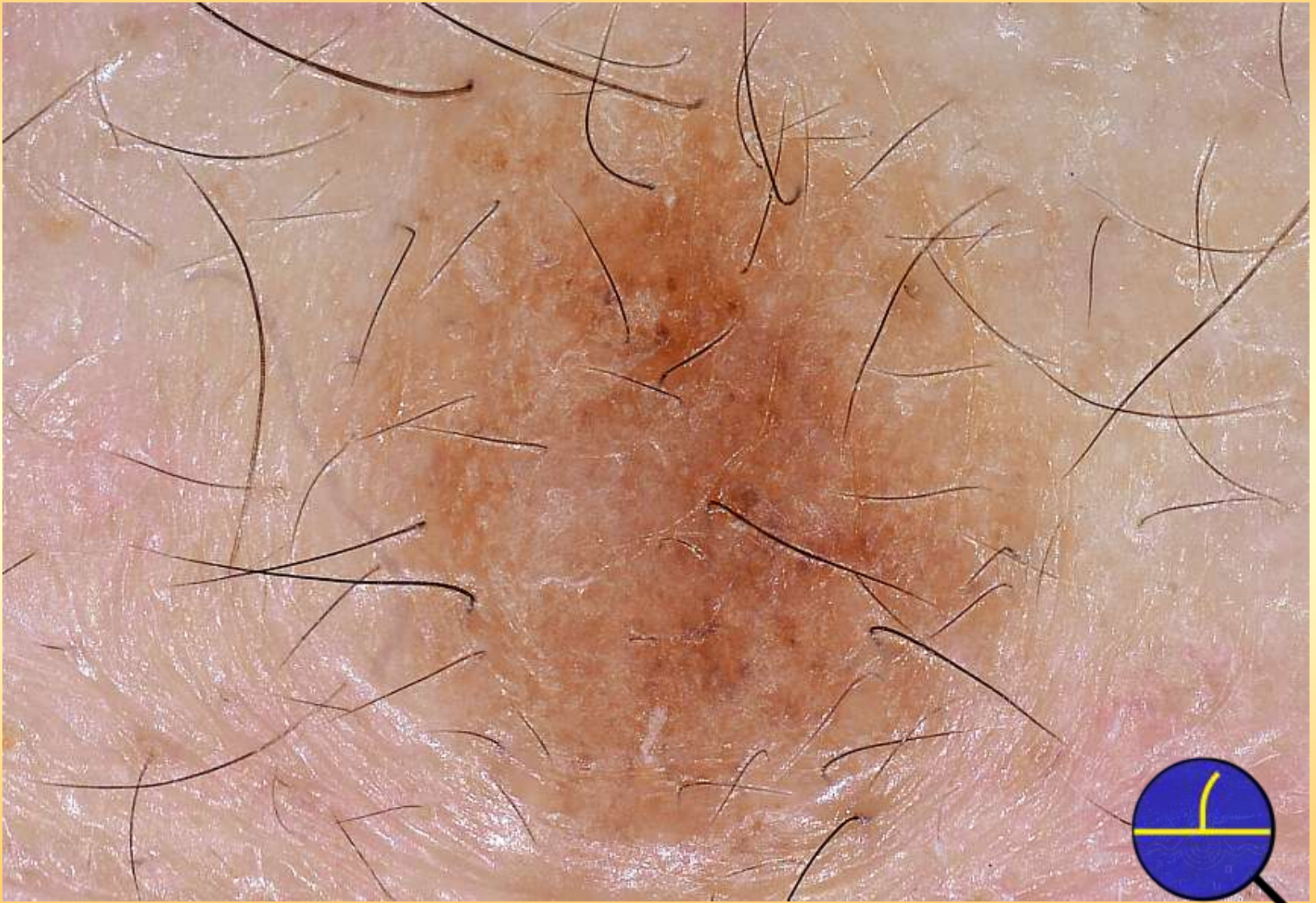Mucous retention cyst



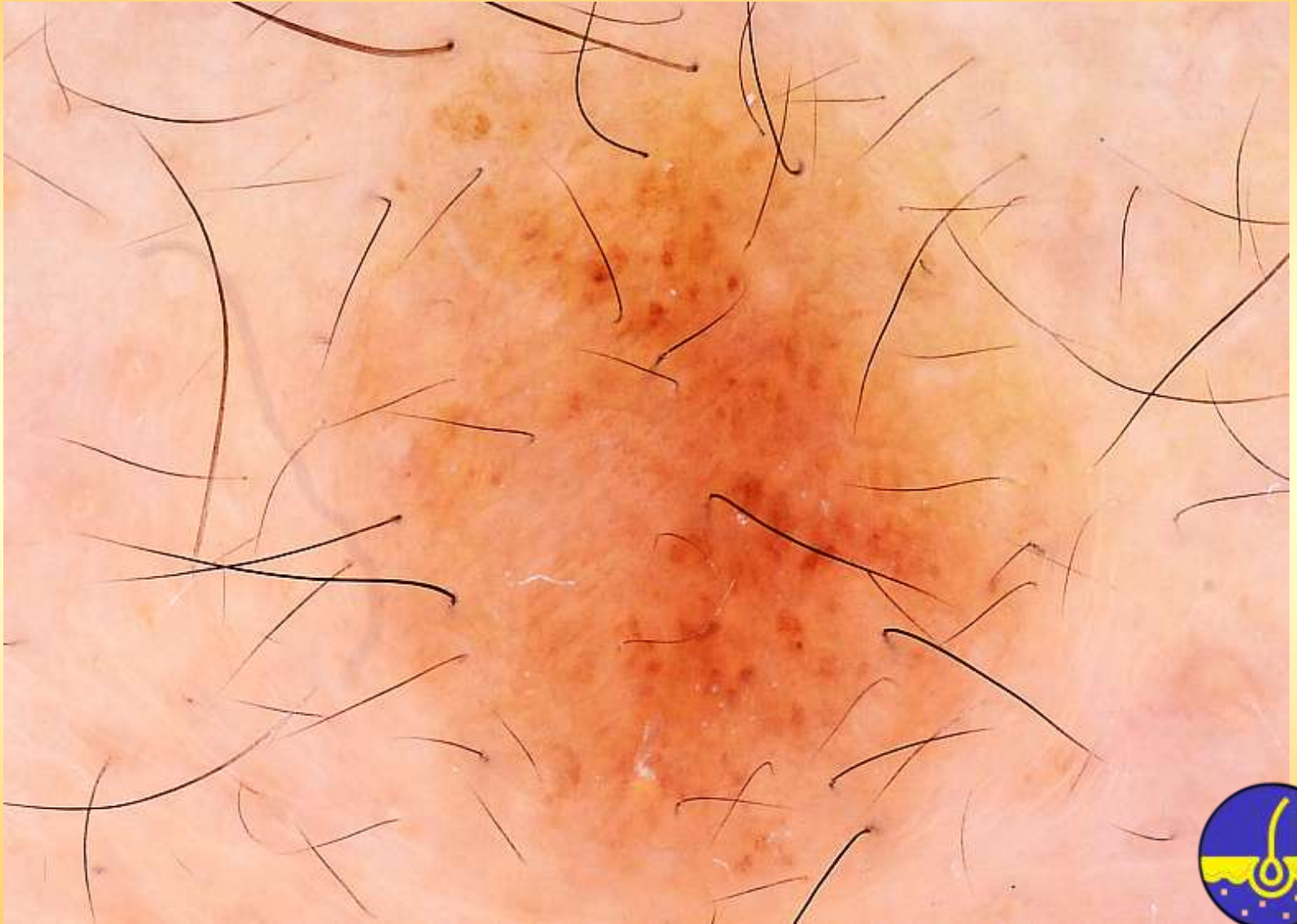
Quiz – dermoscopy



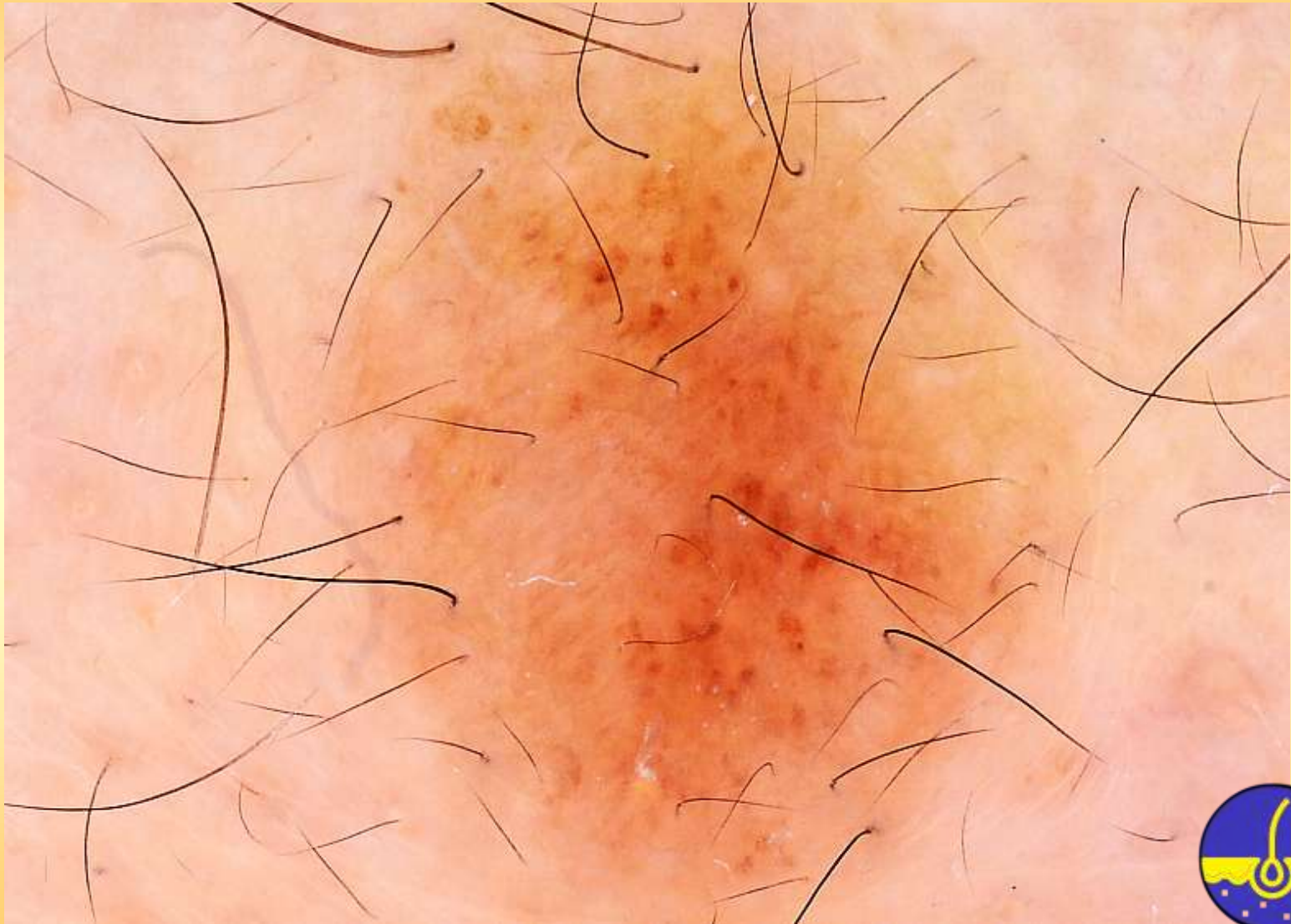Quiz – dermoscopy



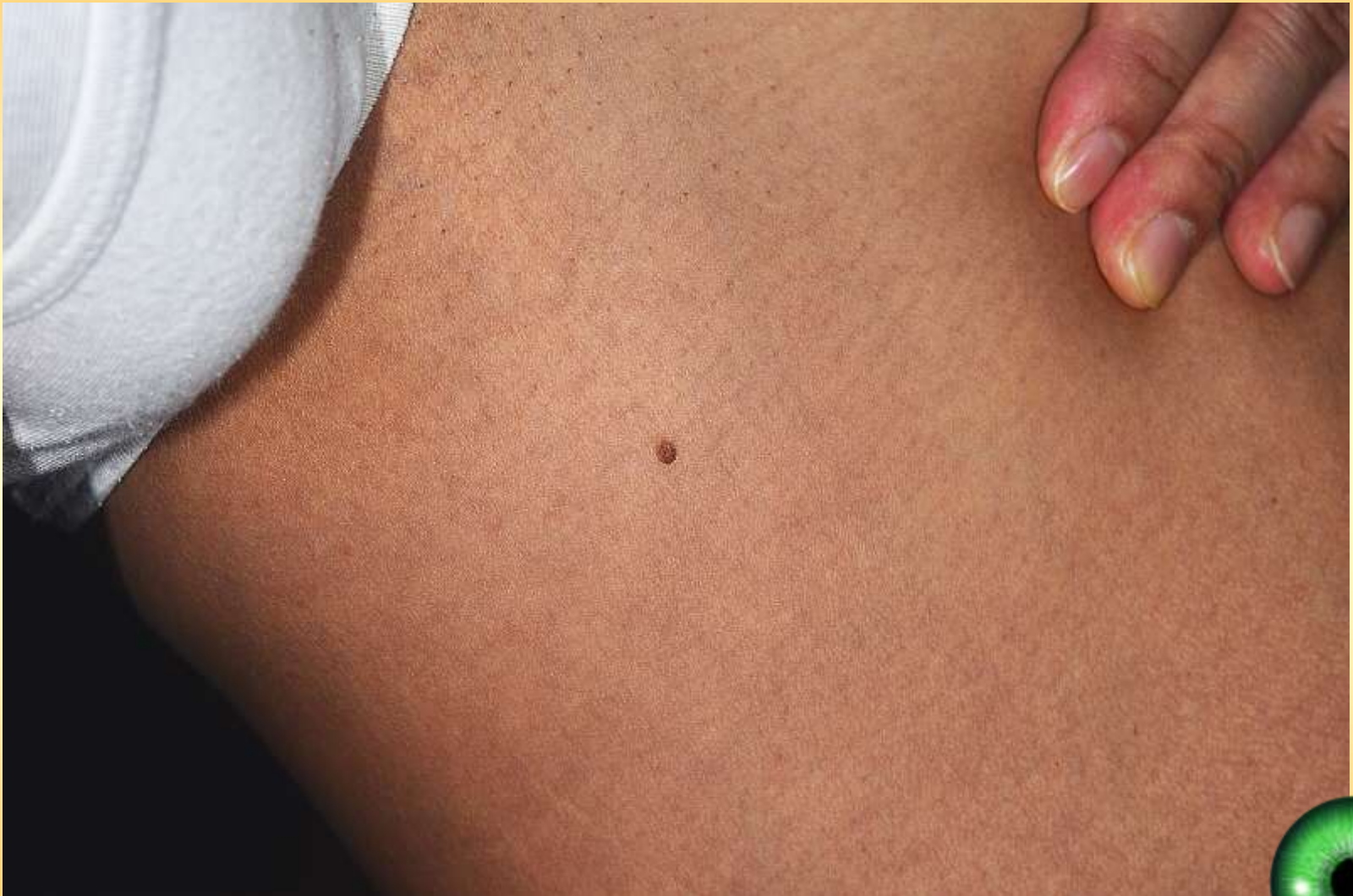?



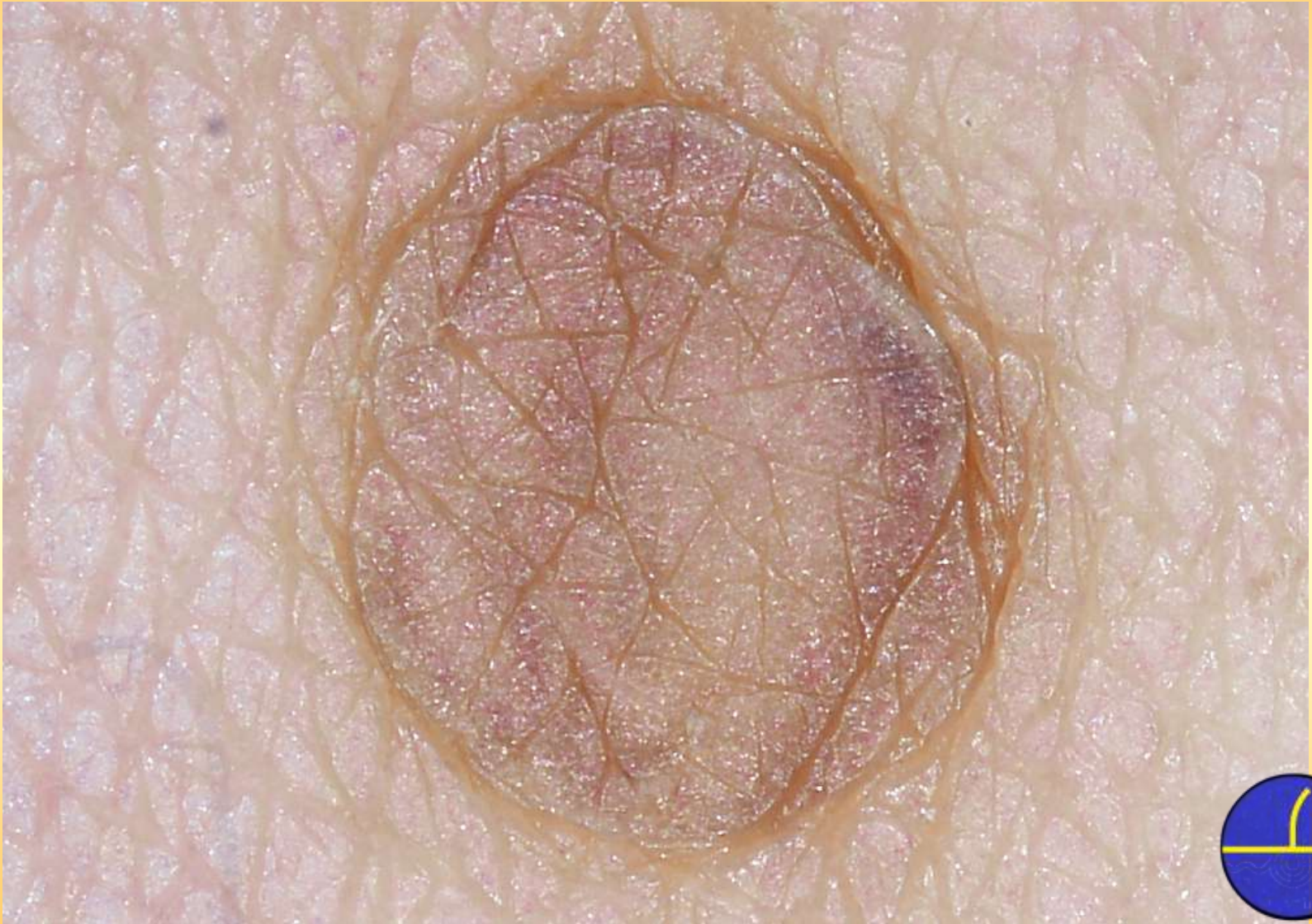
Dermal Naevus



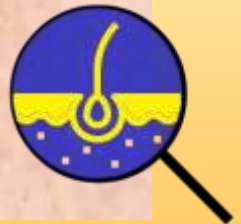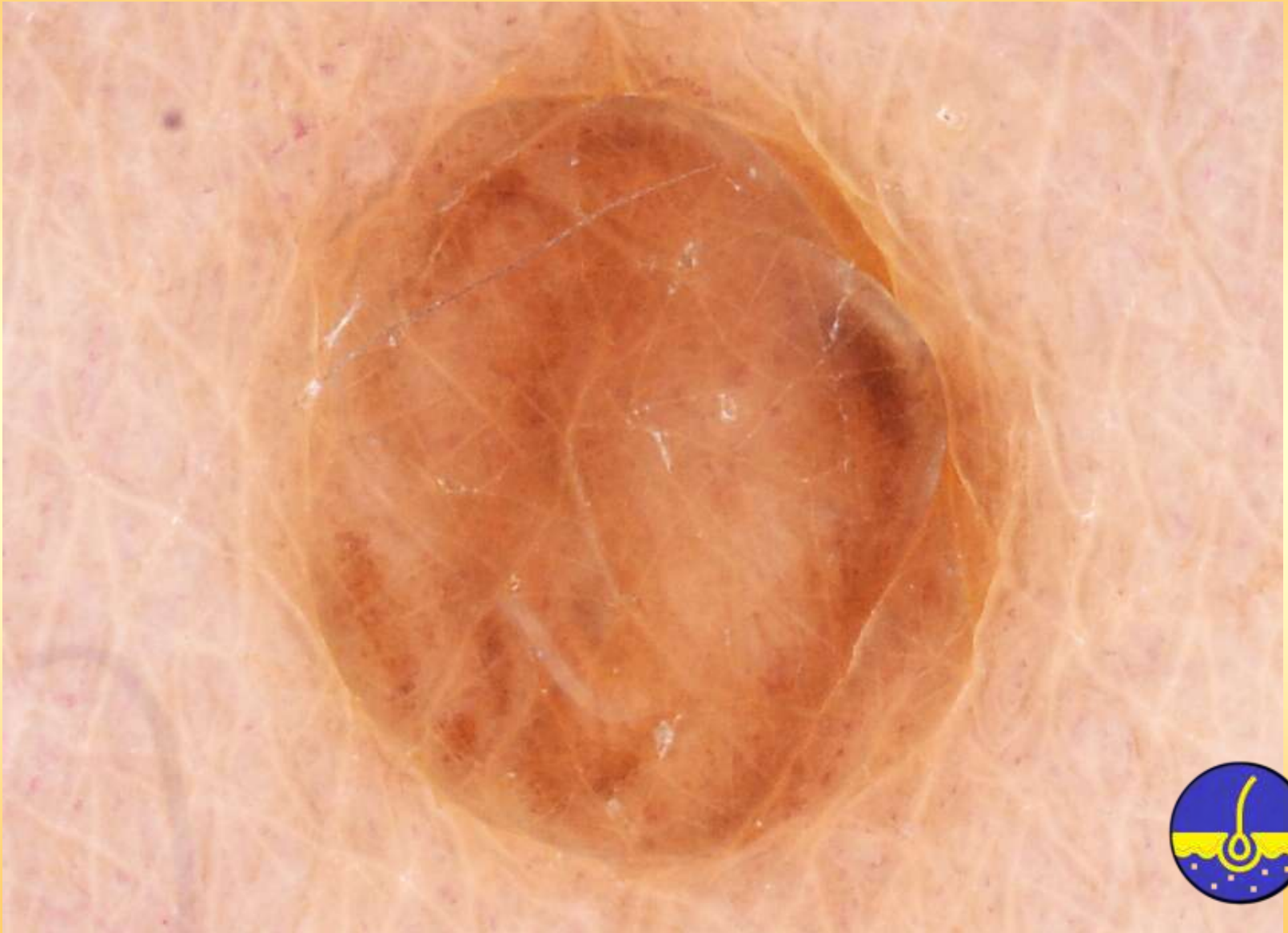
Quiz – dermoscopy



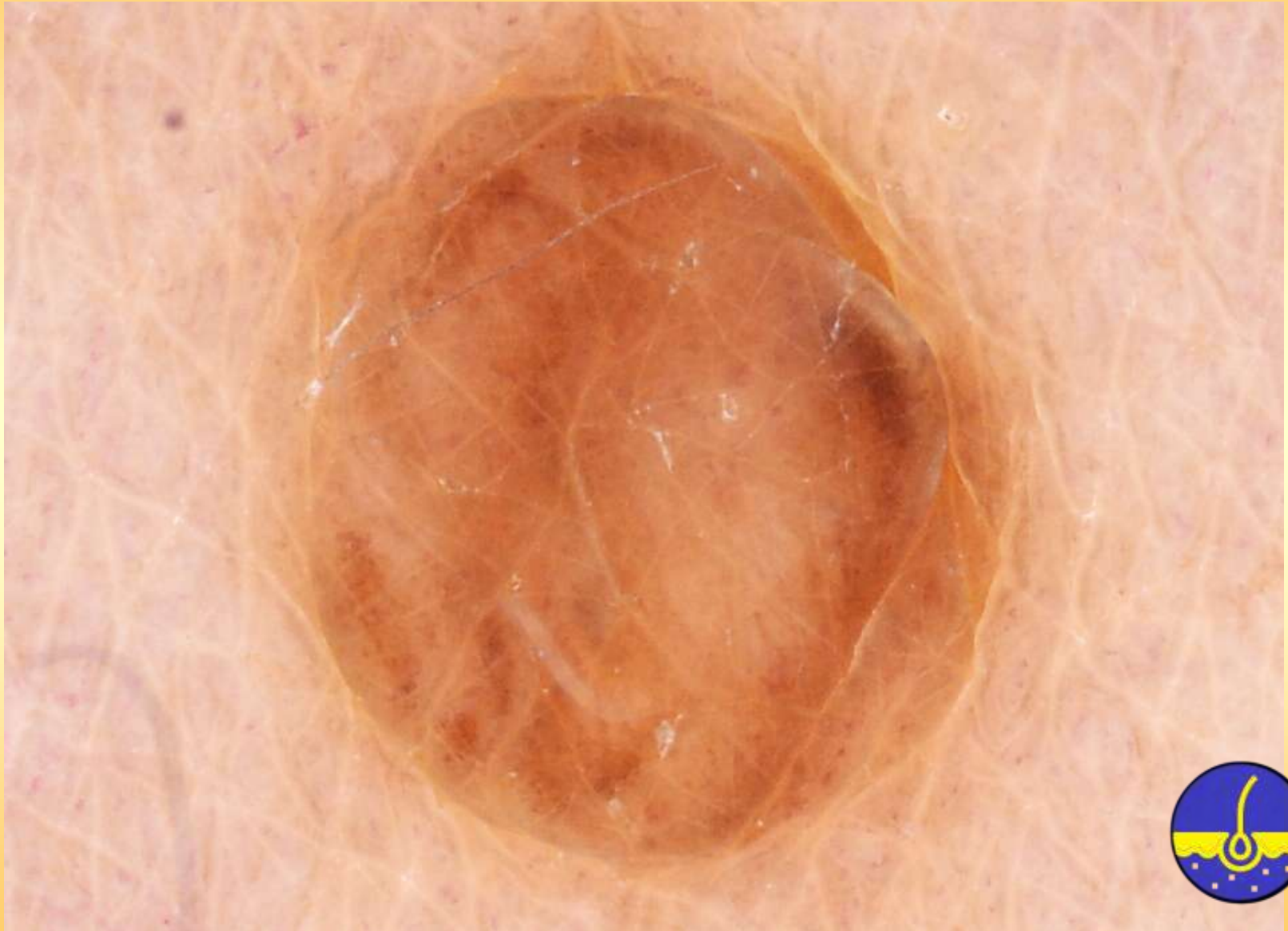
Quiz – dermoscopy



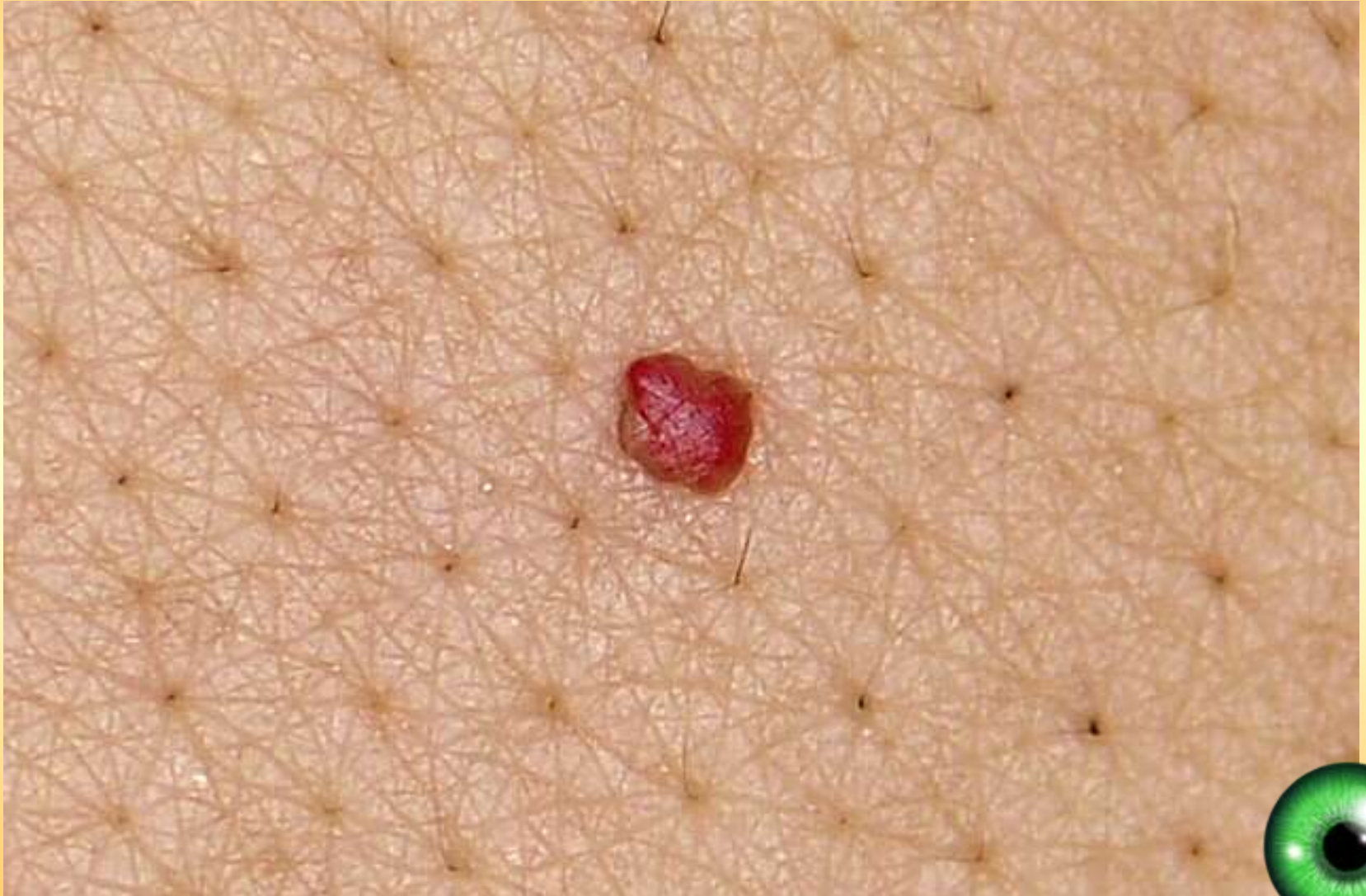?



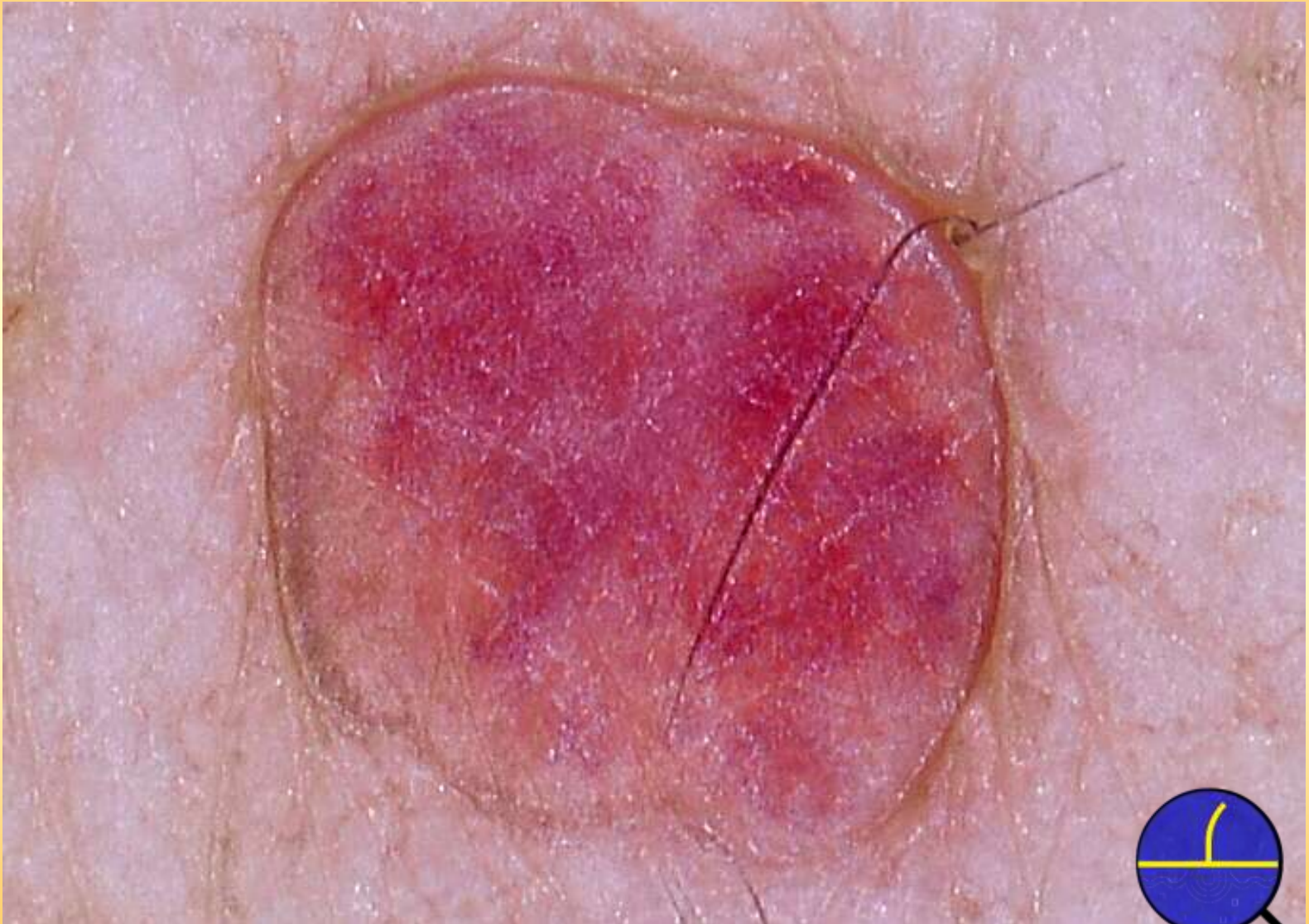
Acrochordon



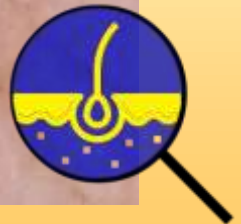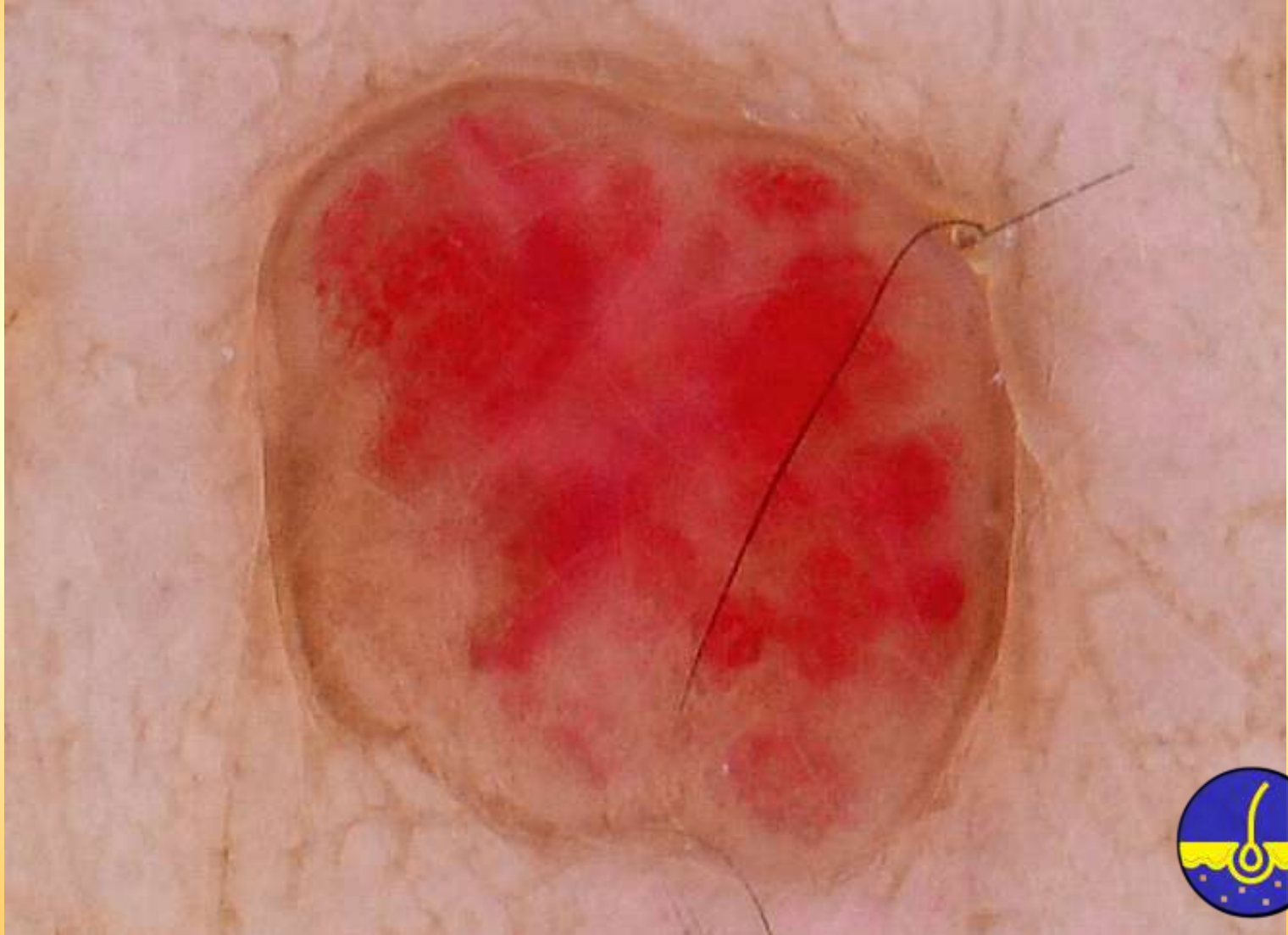
Quiz – dermoscopy



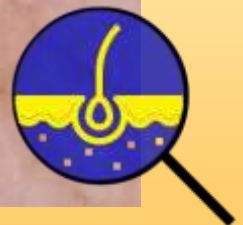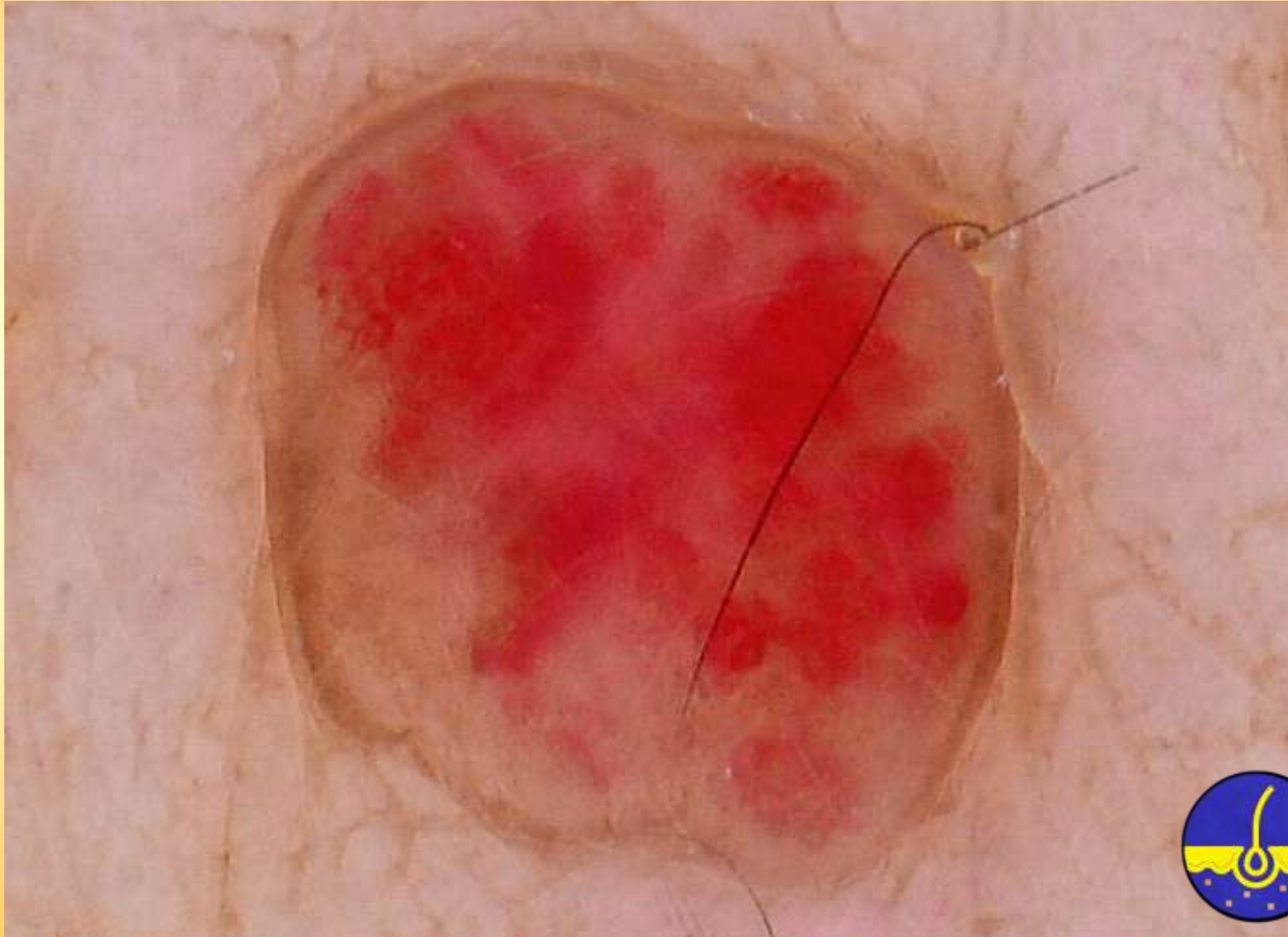
Quiz – dermoscopy



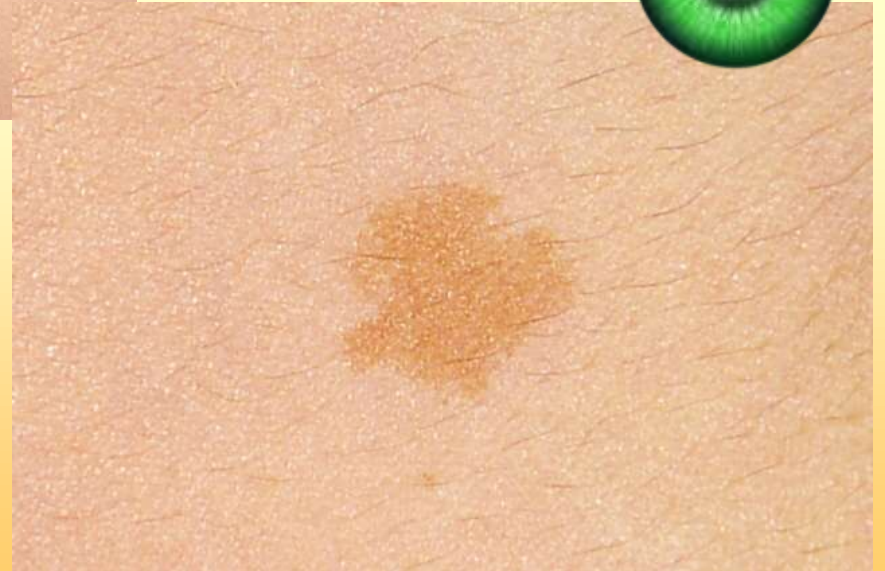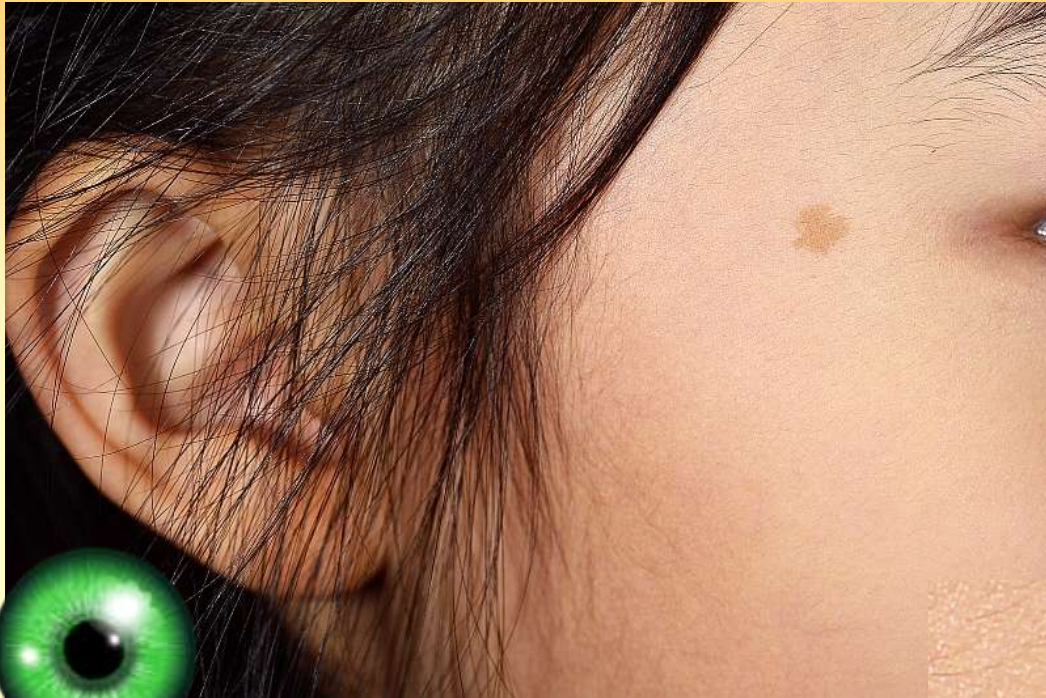?



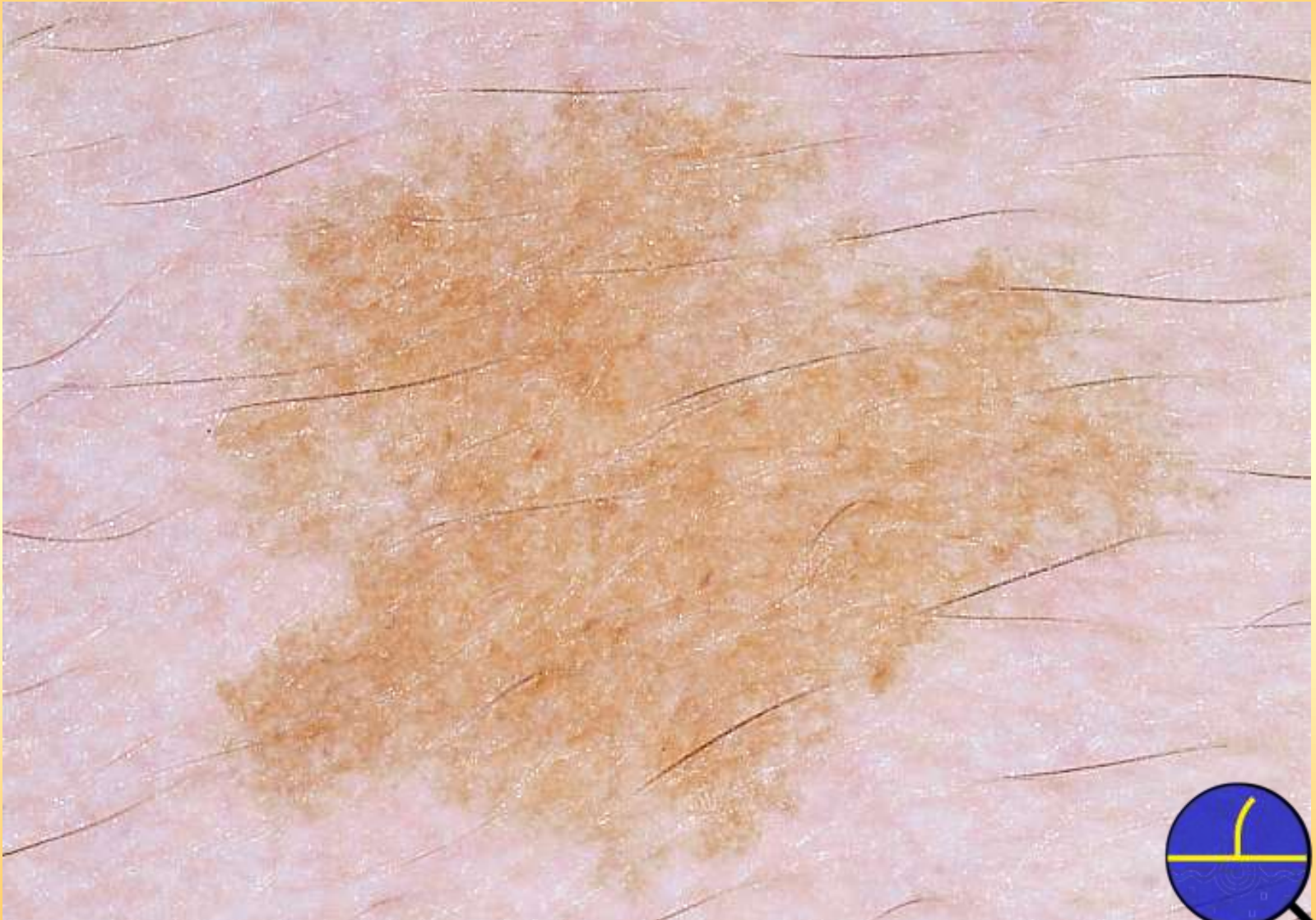
Cherry haemangioma



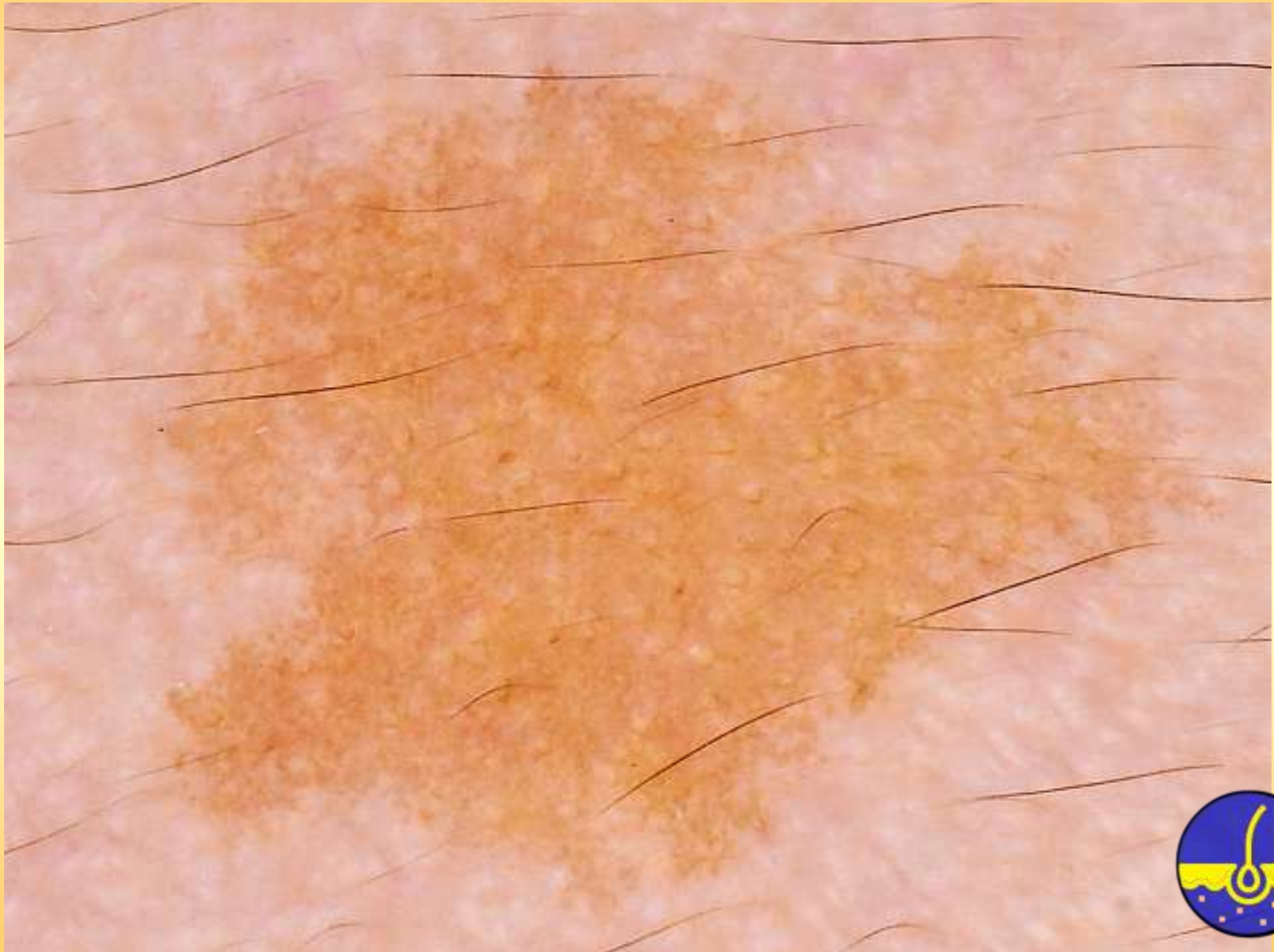Quiz – dermoscopy



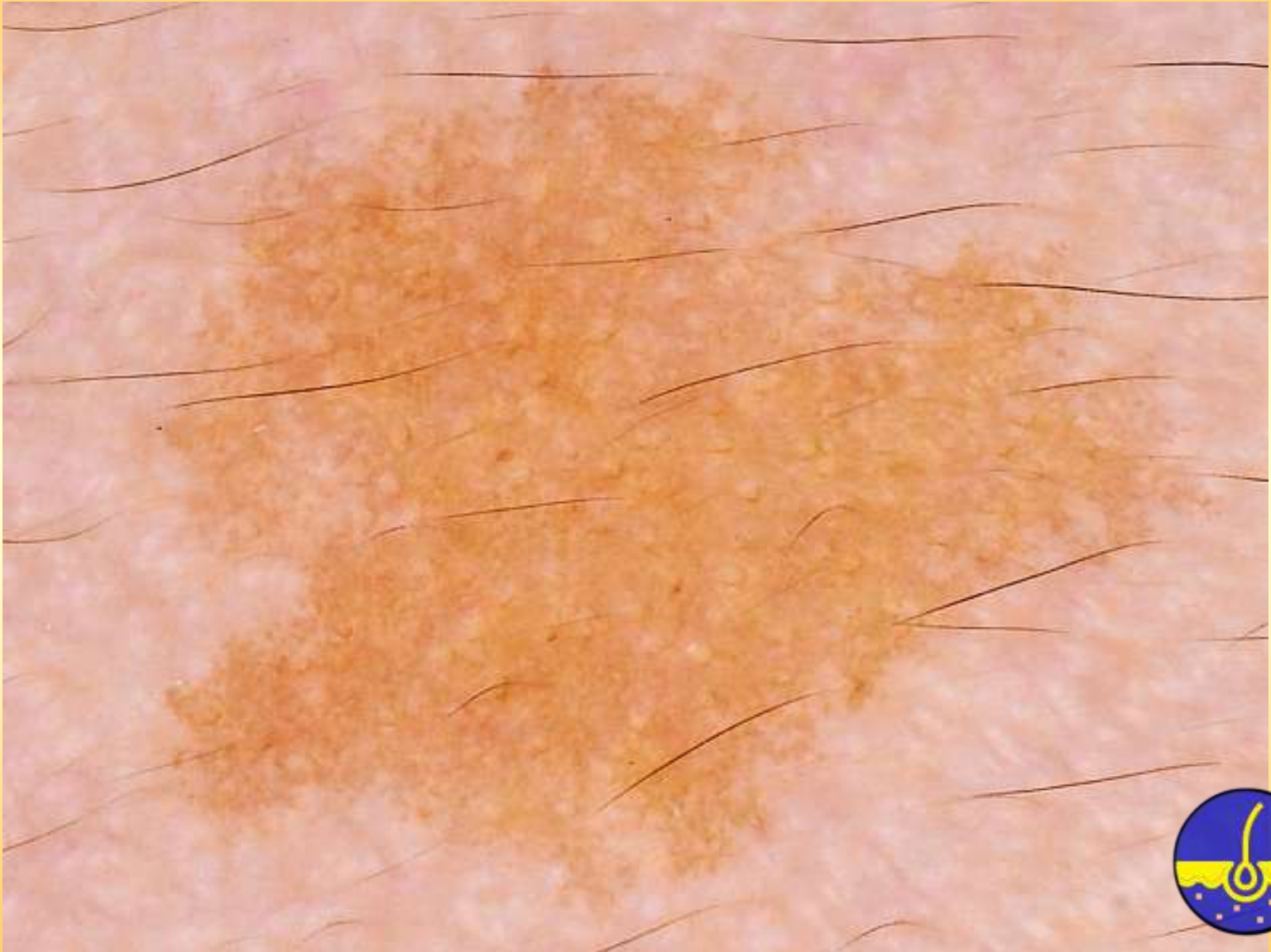Quiz – dermoscopy



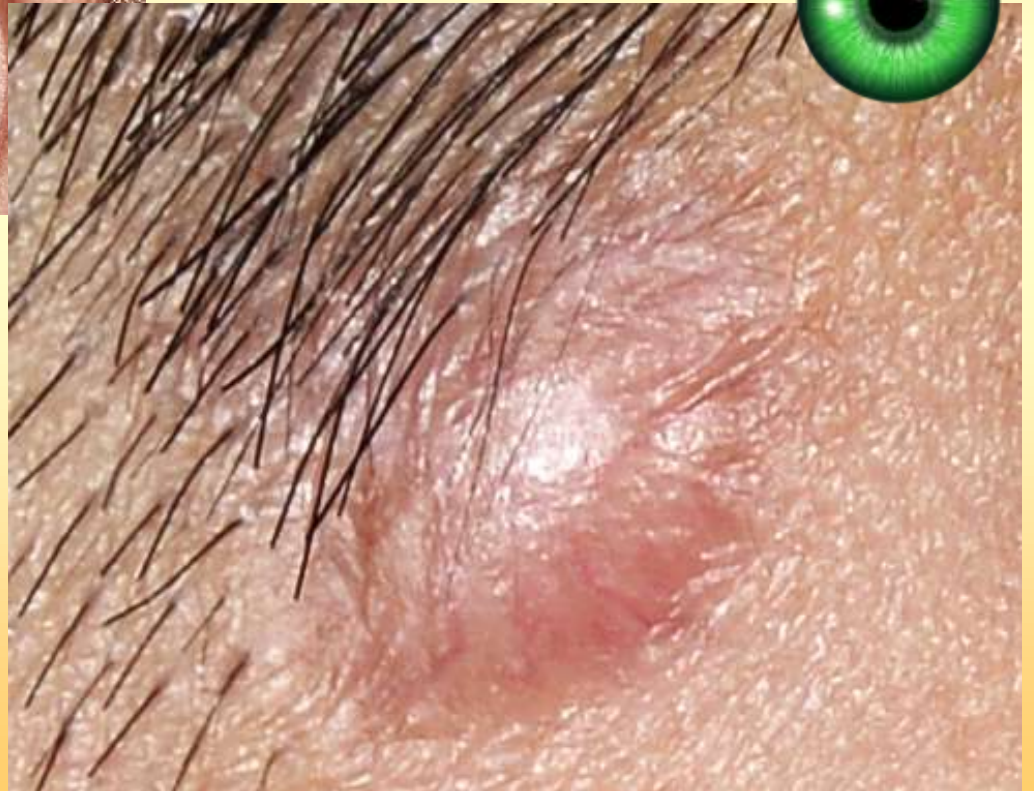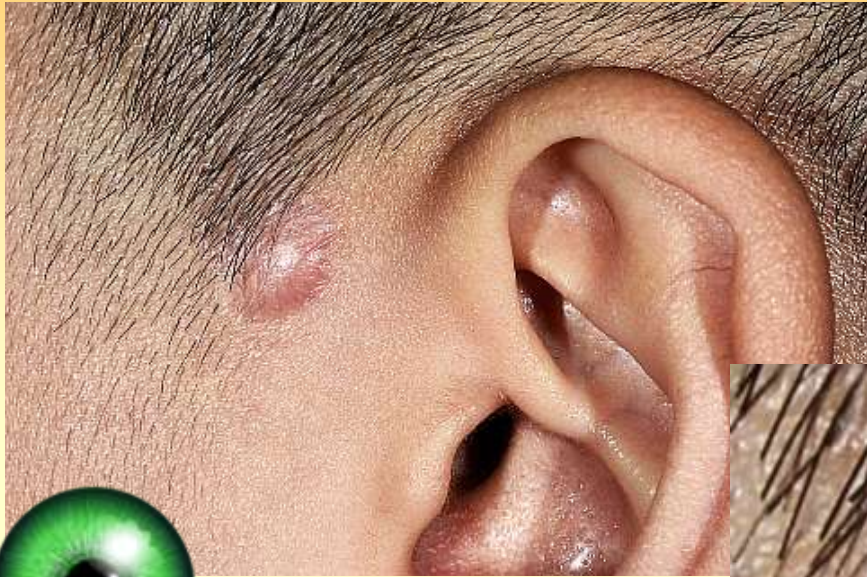Quiz – dermoscopy



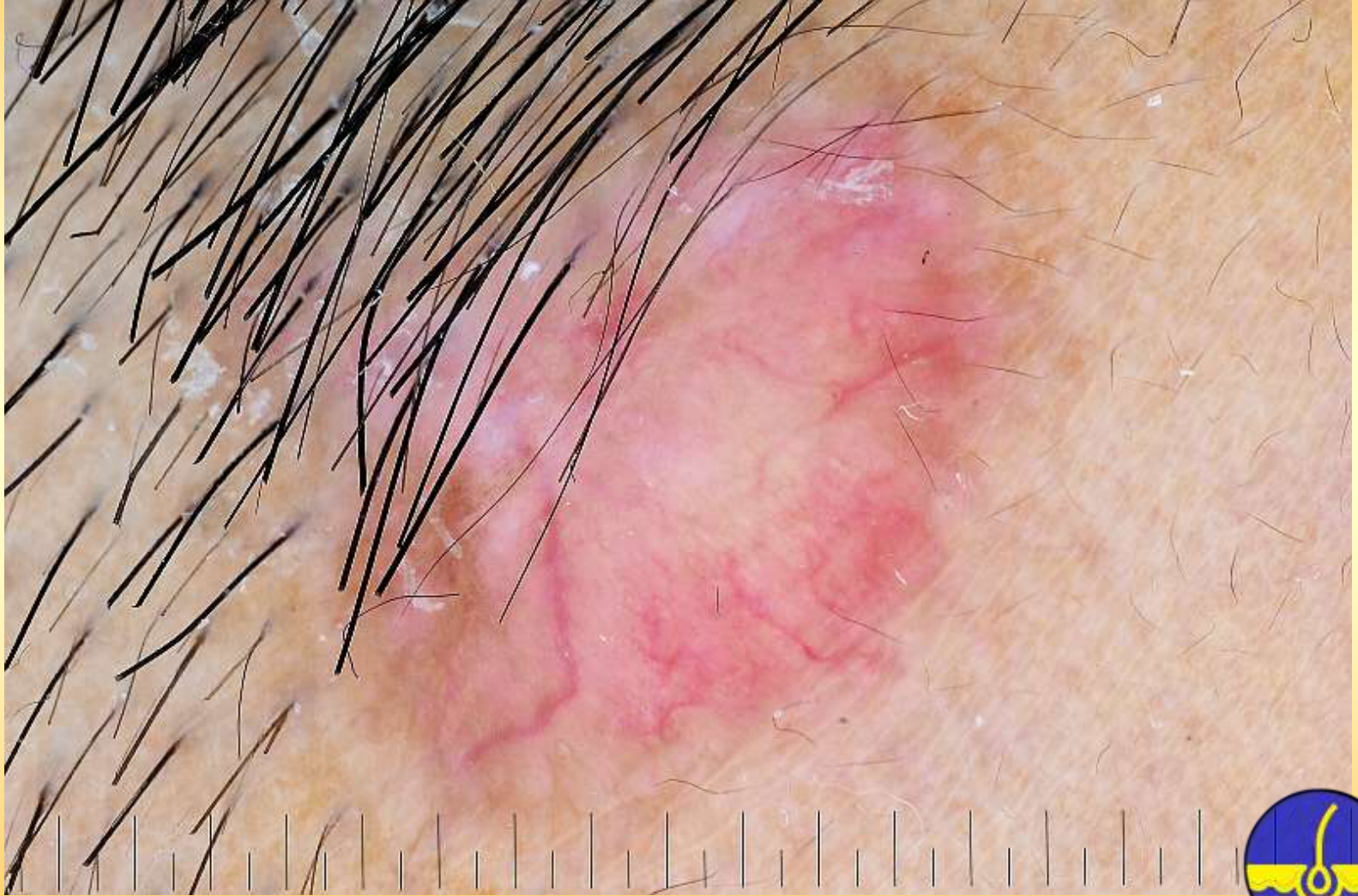Solar lentigo



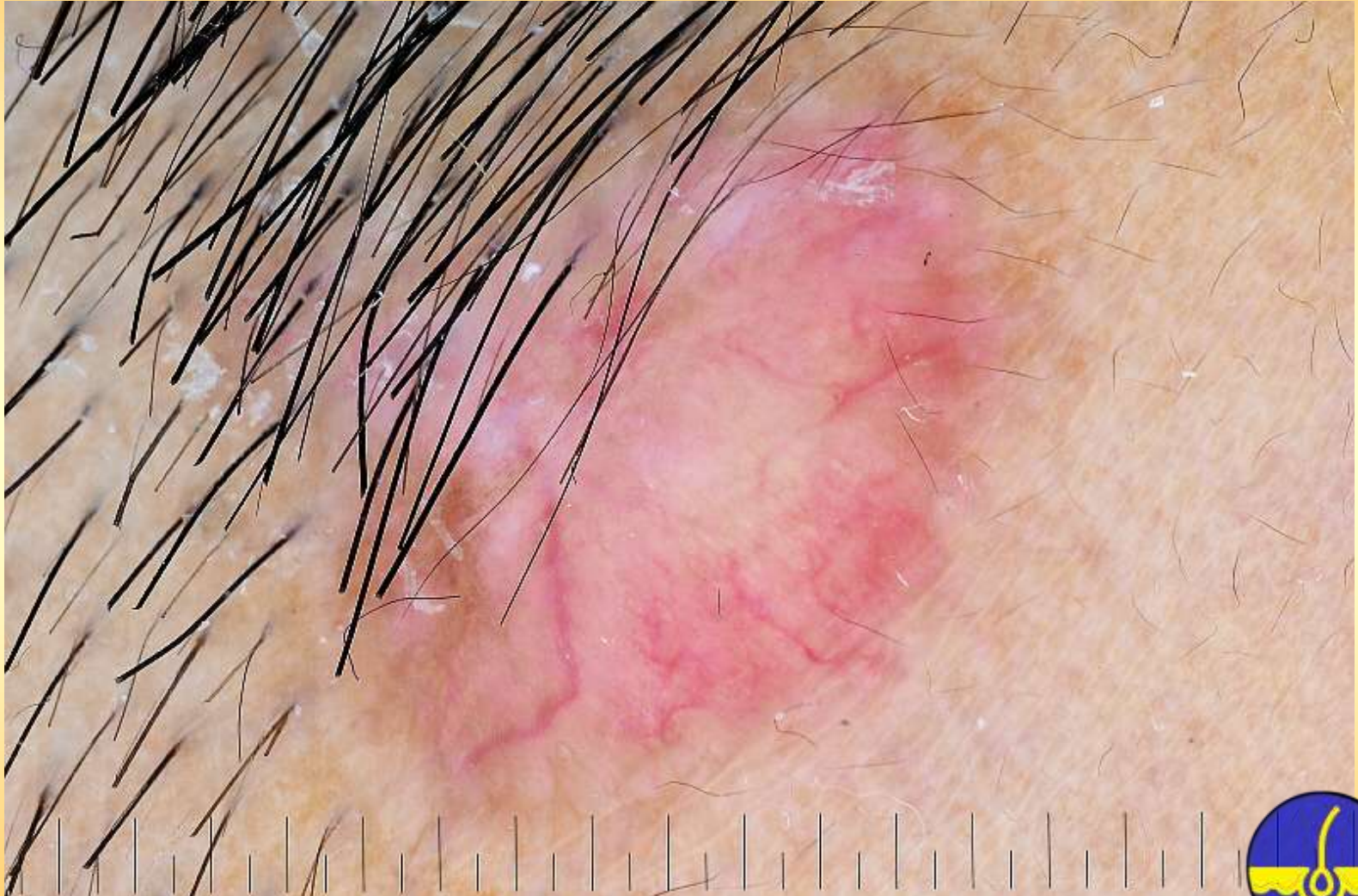Quiz – dermoscopy



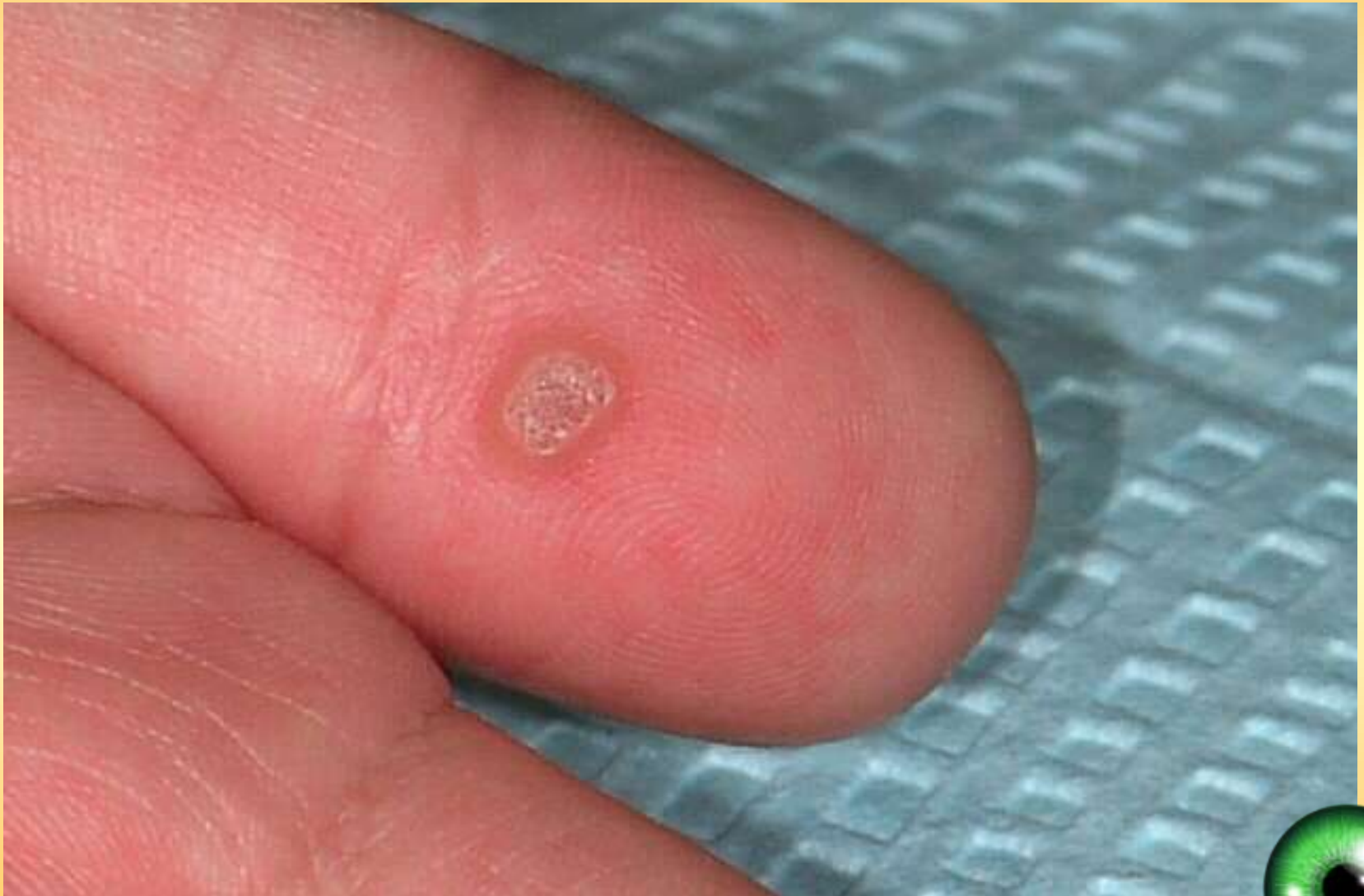?



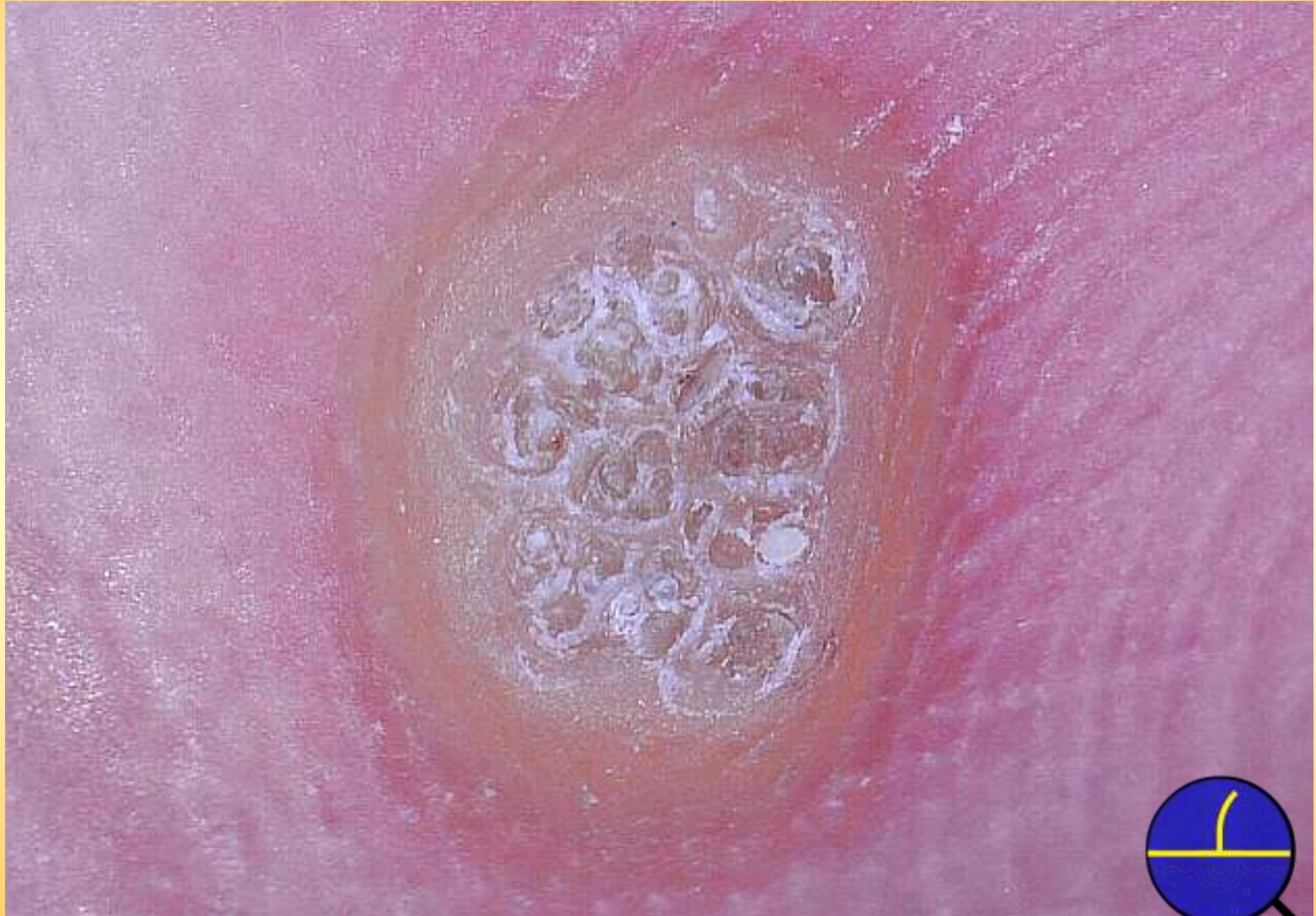Hypertrophic scar / Keloid



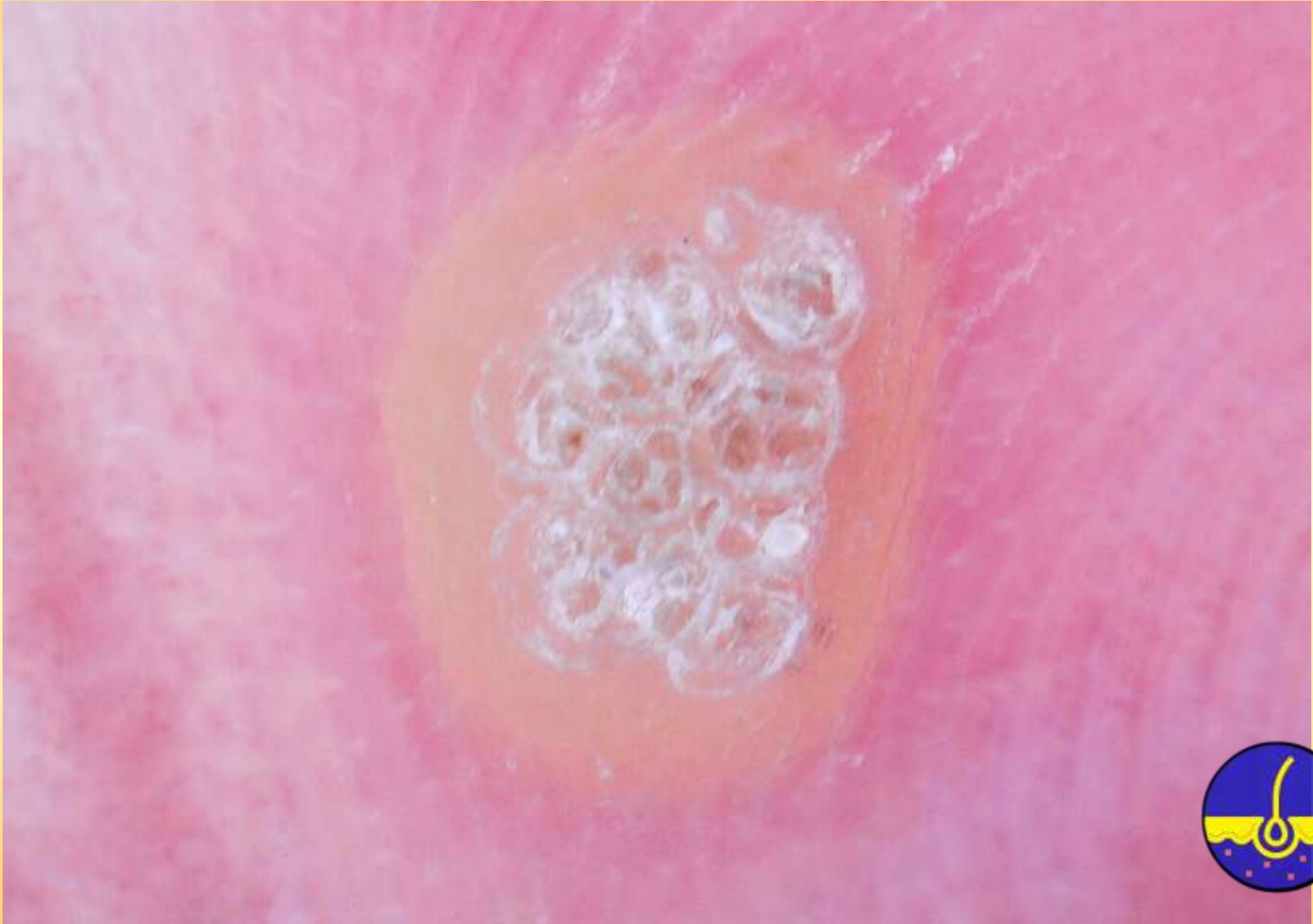Quiz – dermoscopy



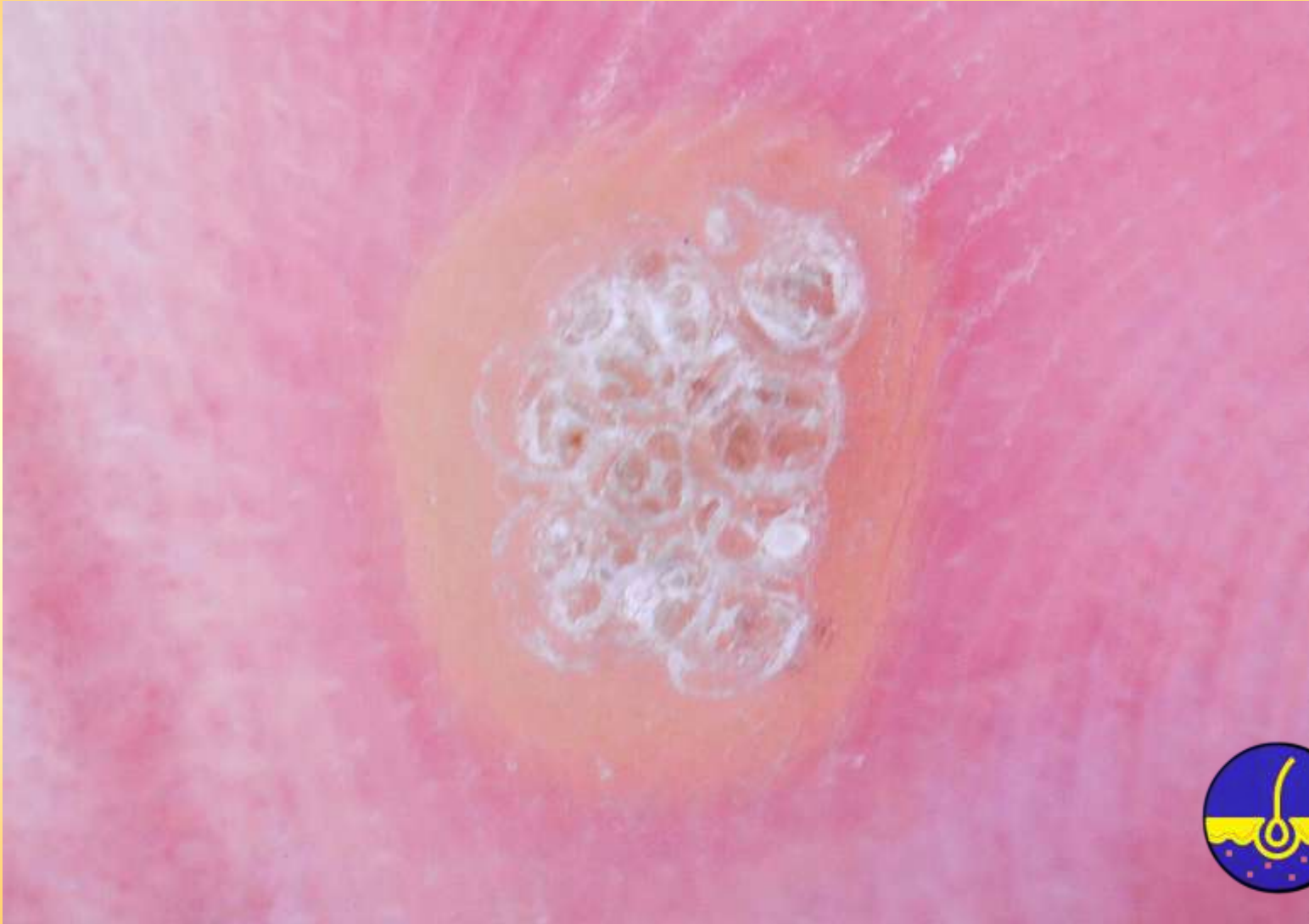Quiz – dermoscopy



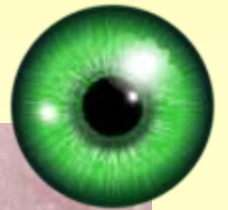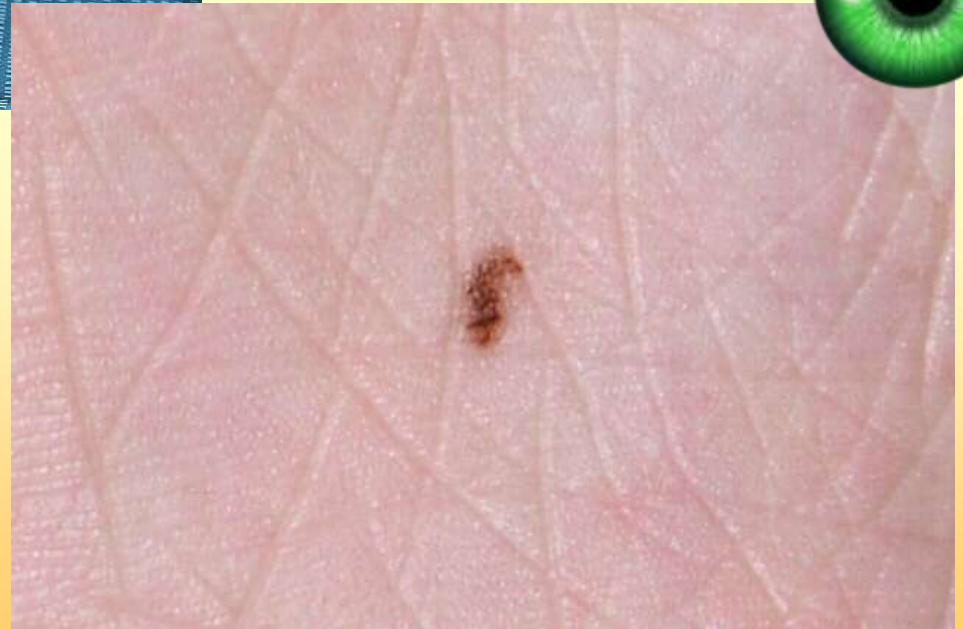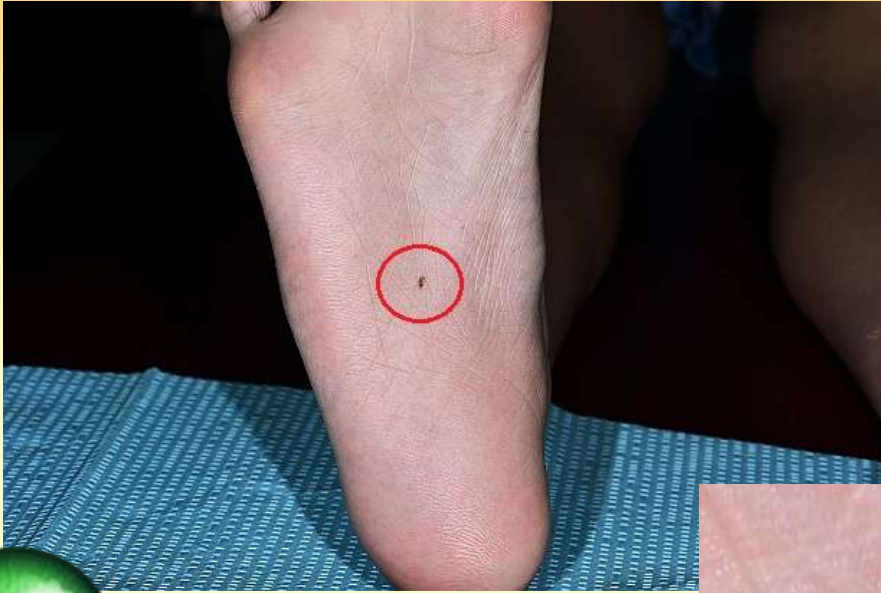?



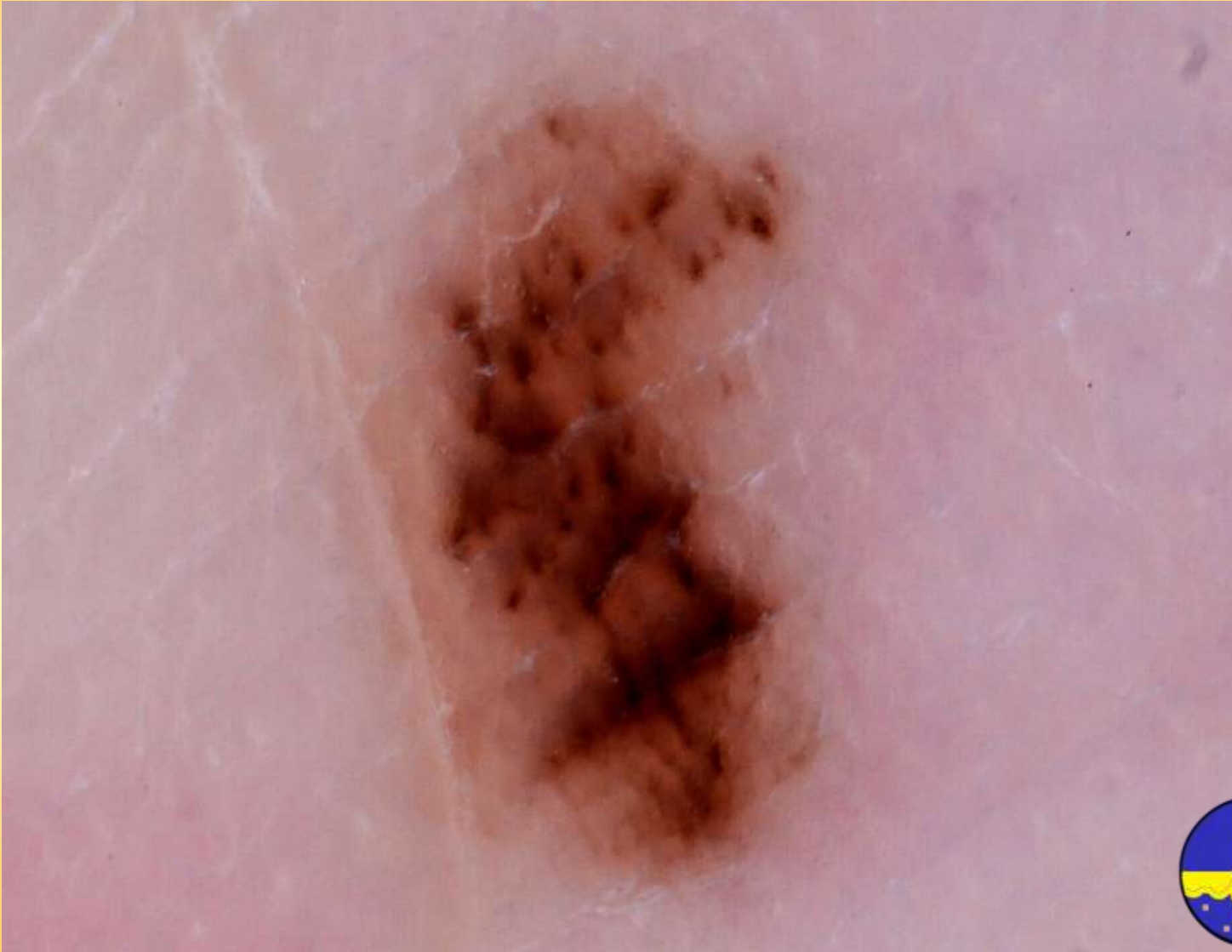
Extragenital viral wart



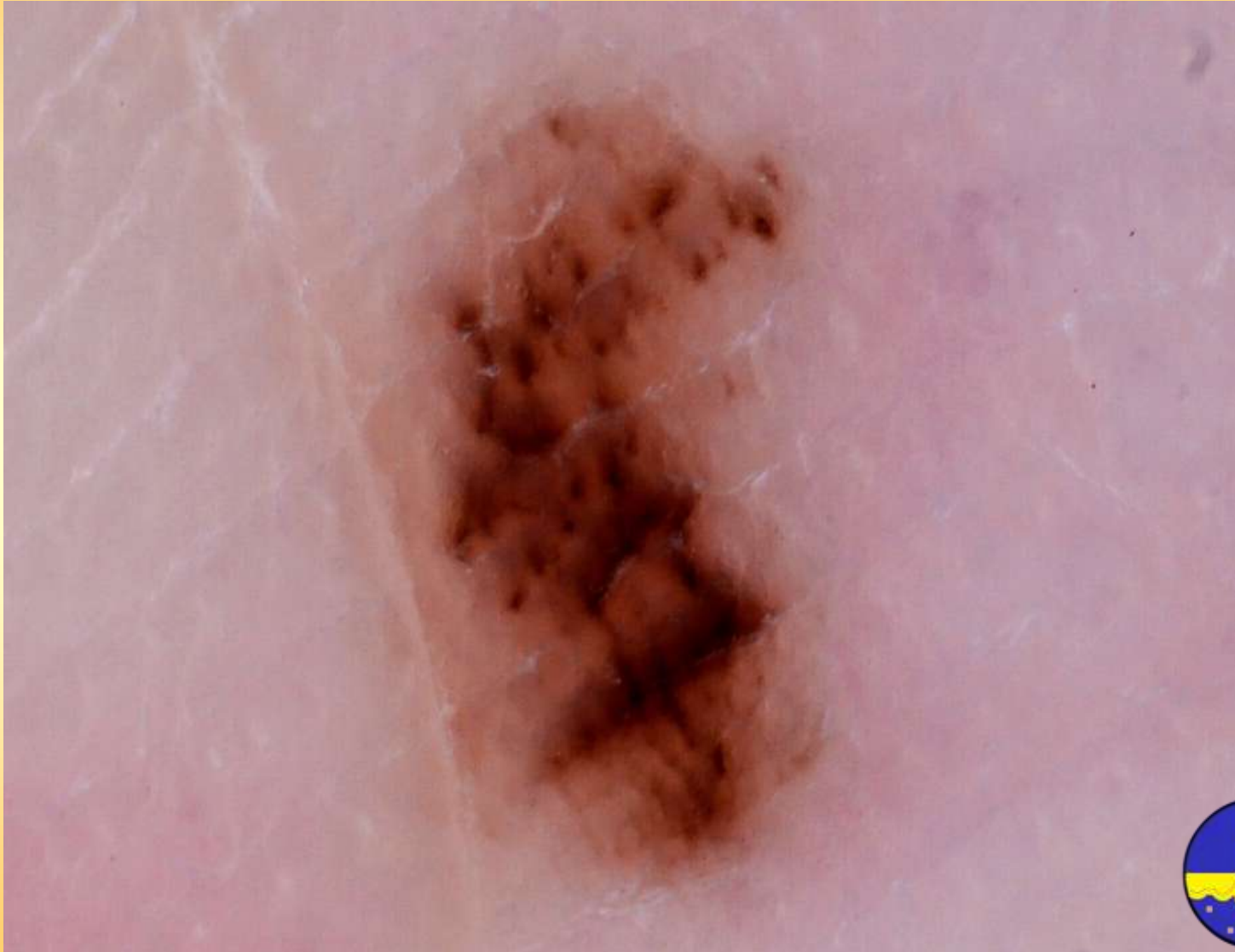Quiz – dermoscopy



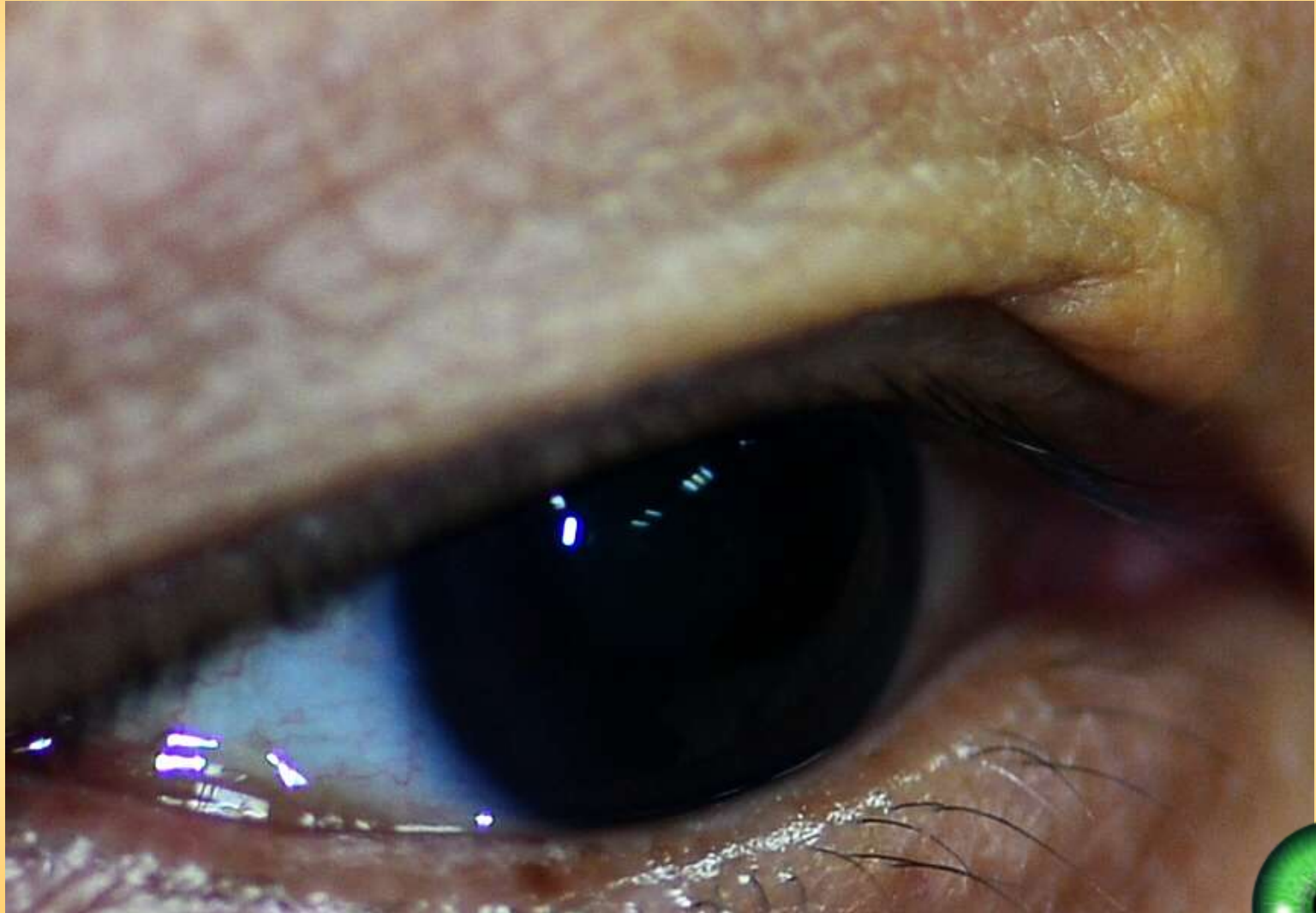
?



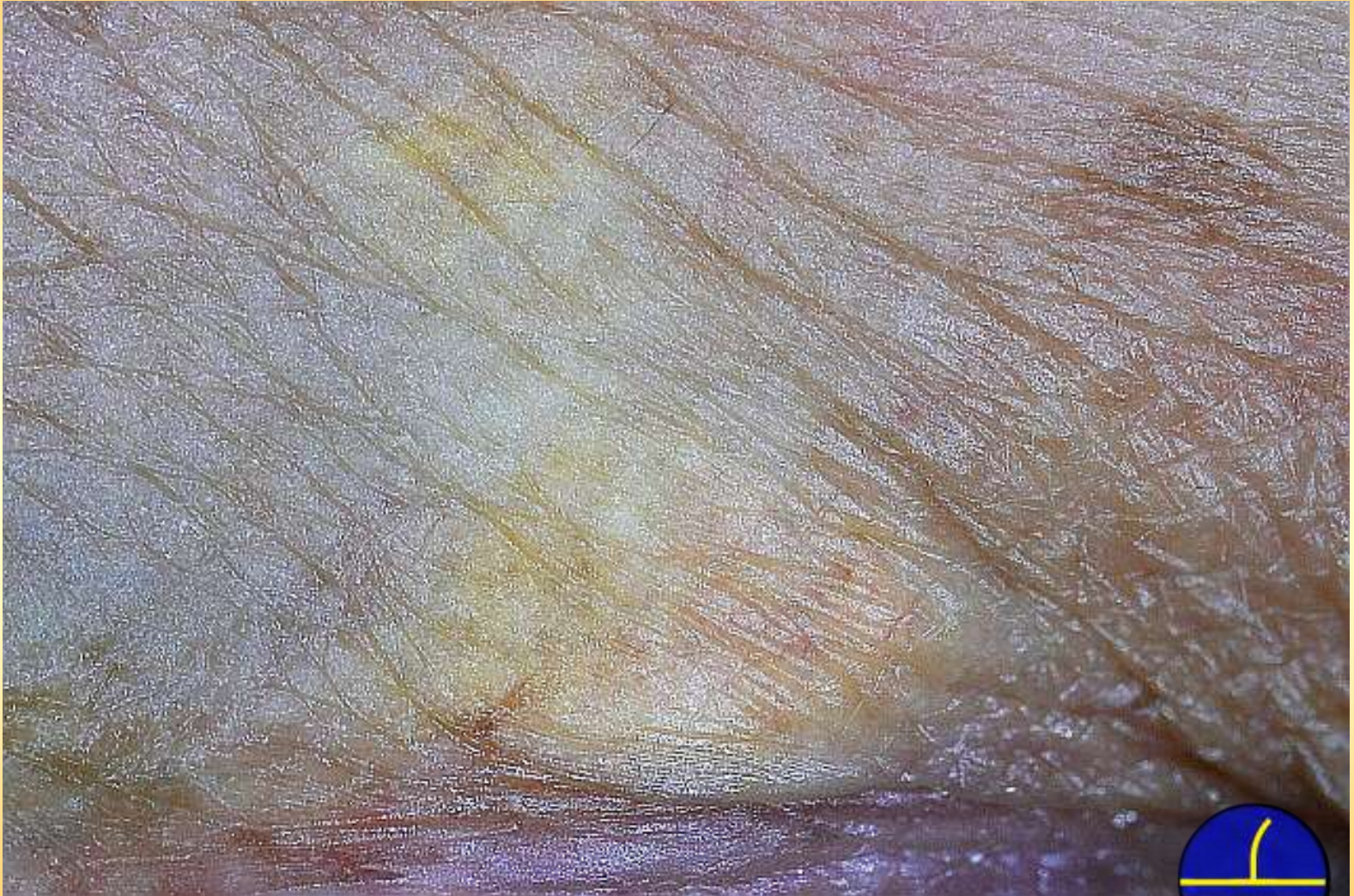
Acral melanocytic naevus



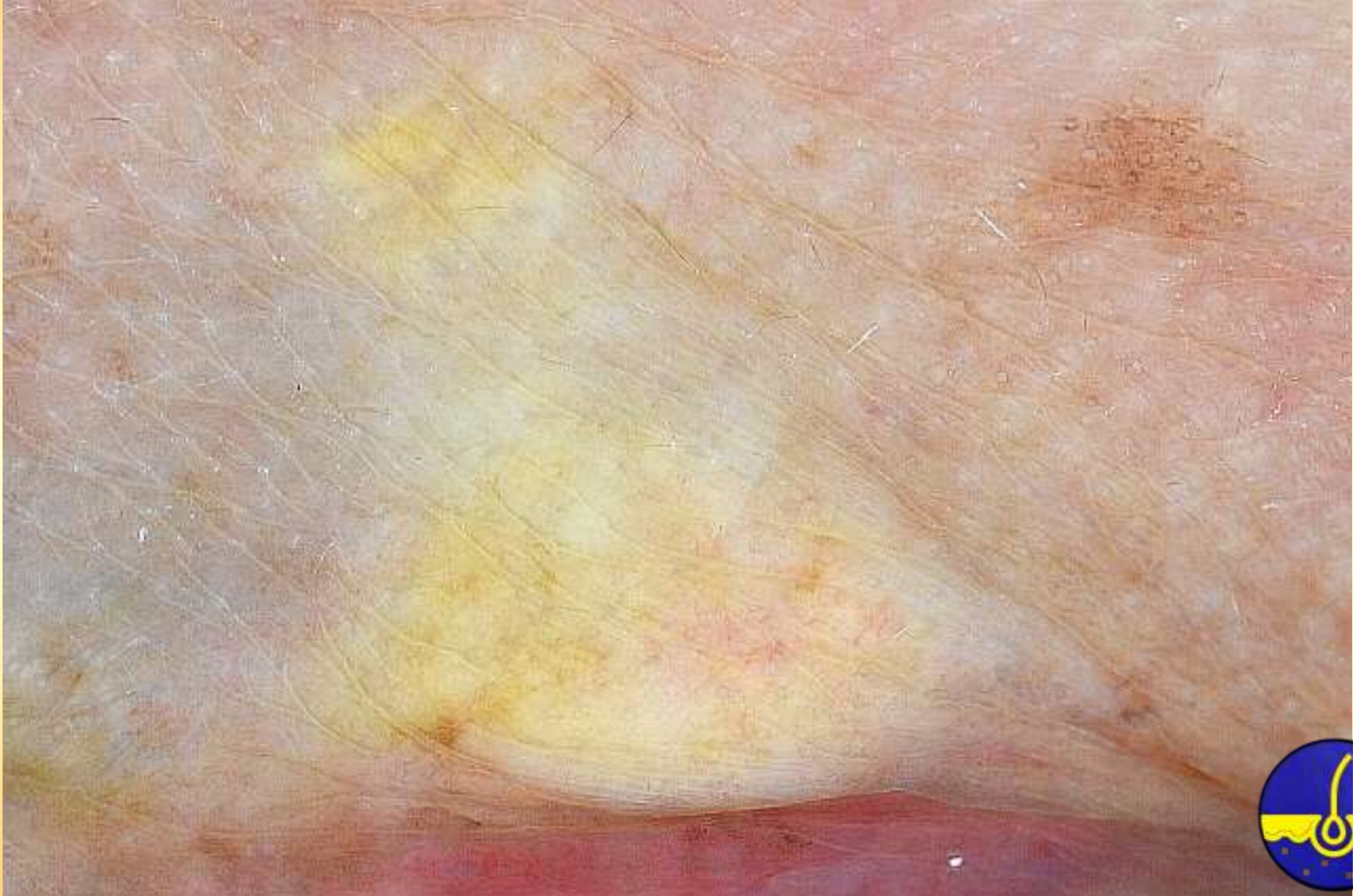Quiz – dermoscopy



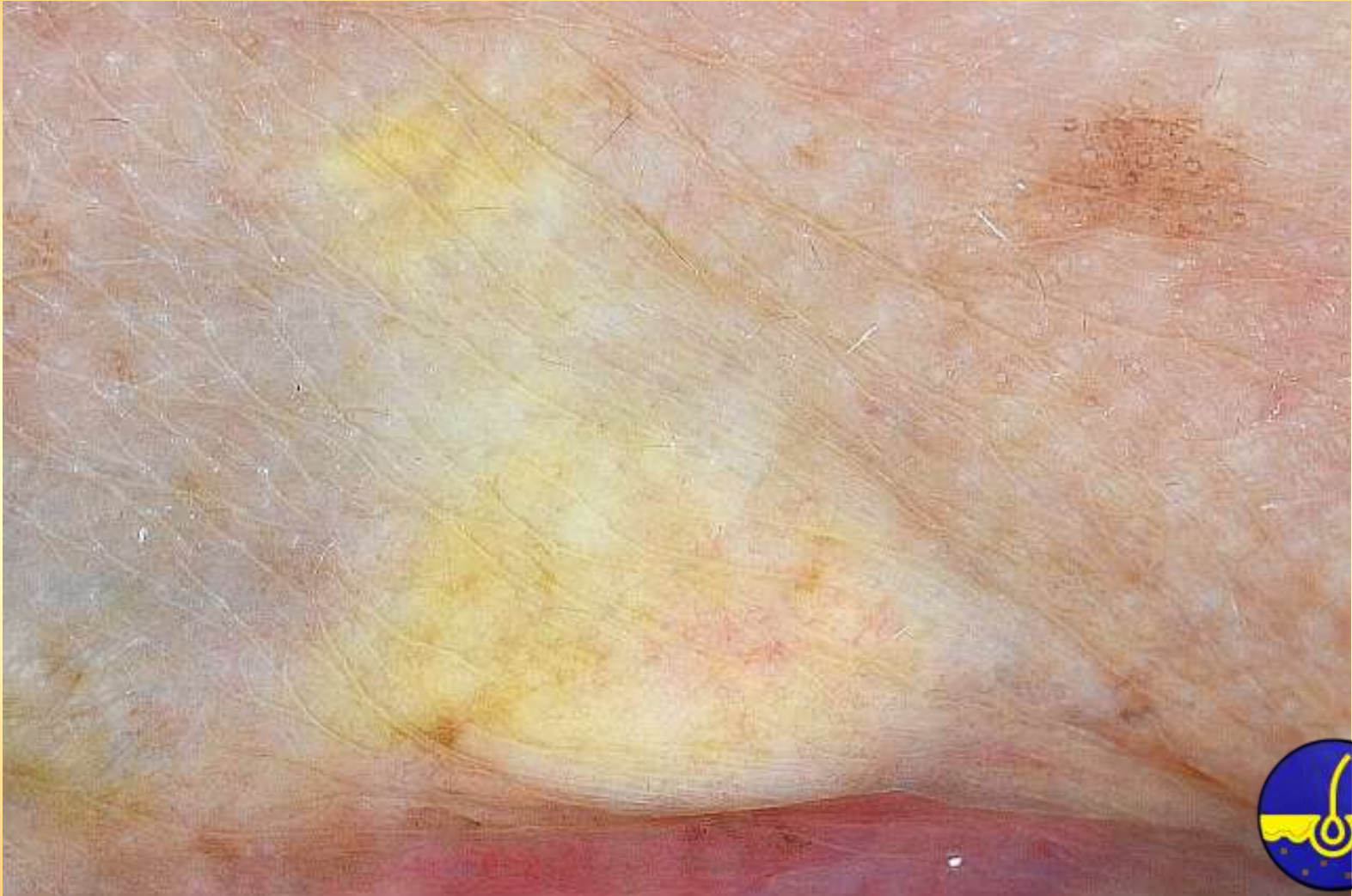Quiz – dermoscopy



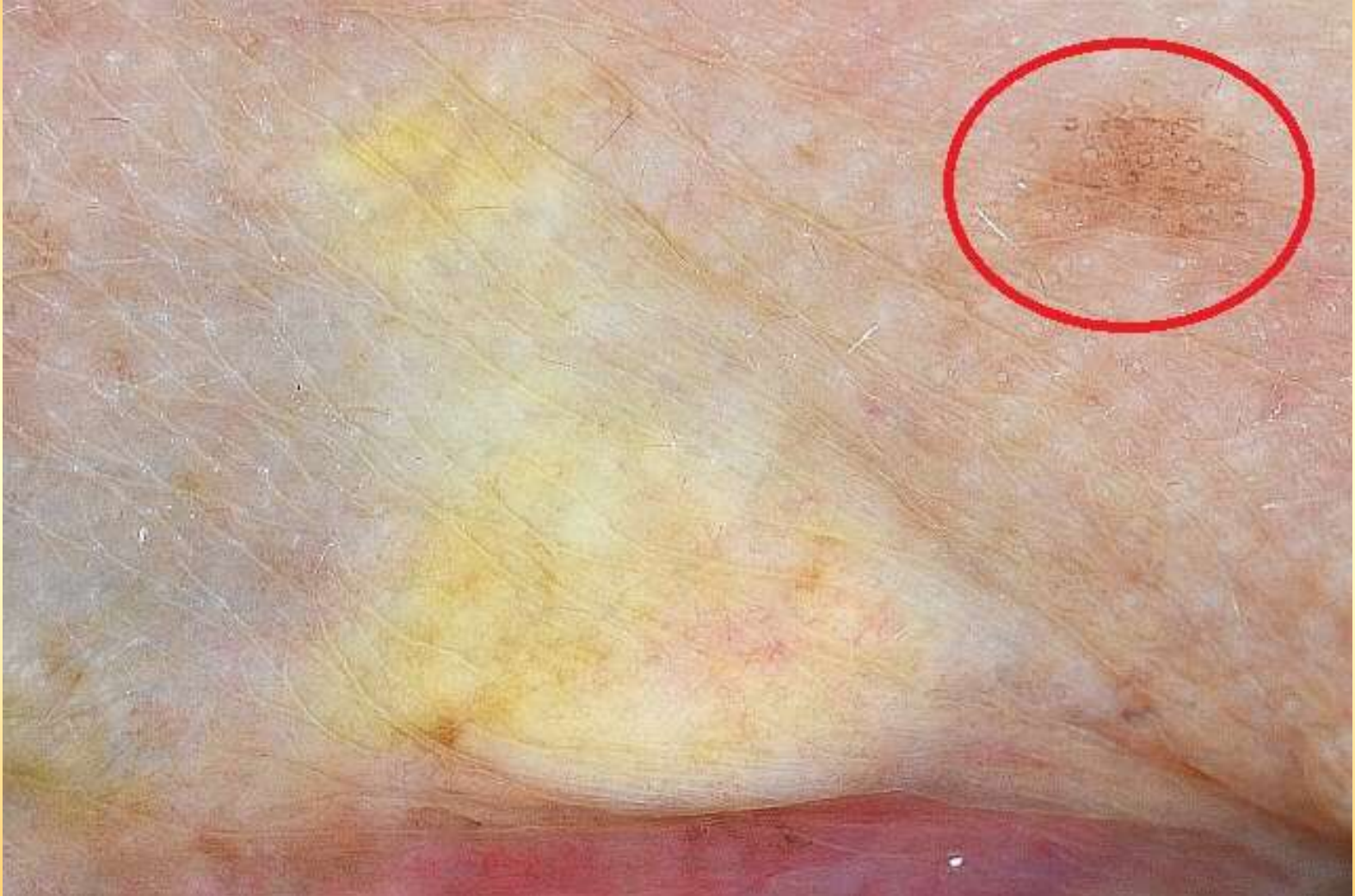?



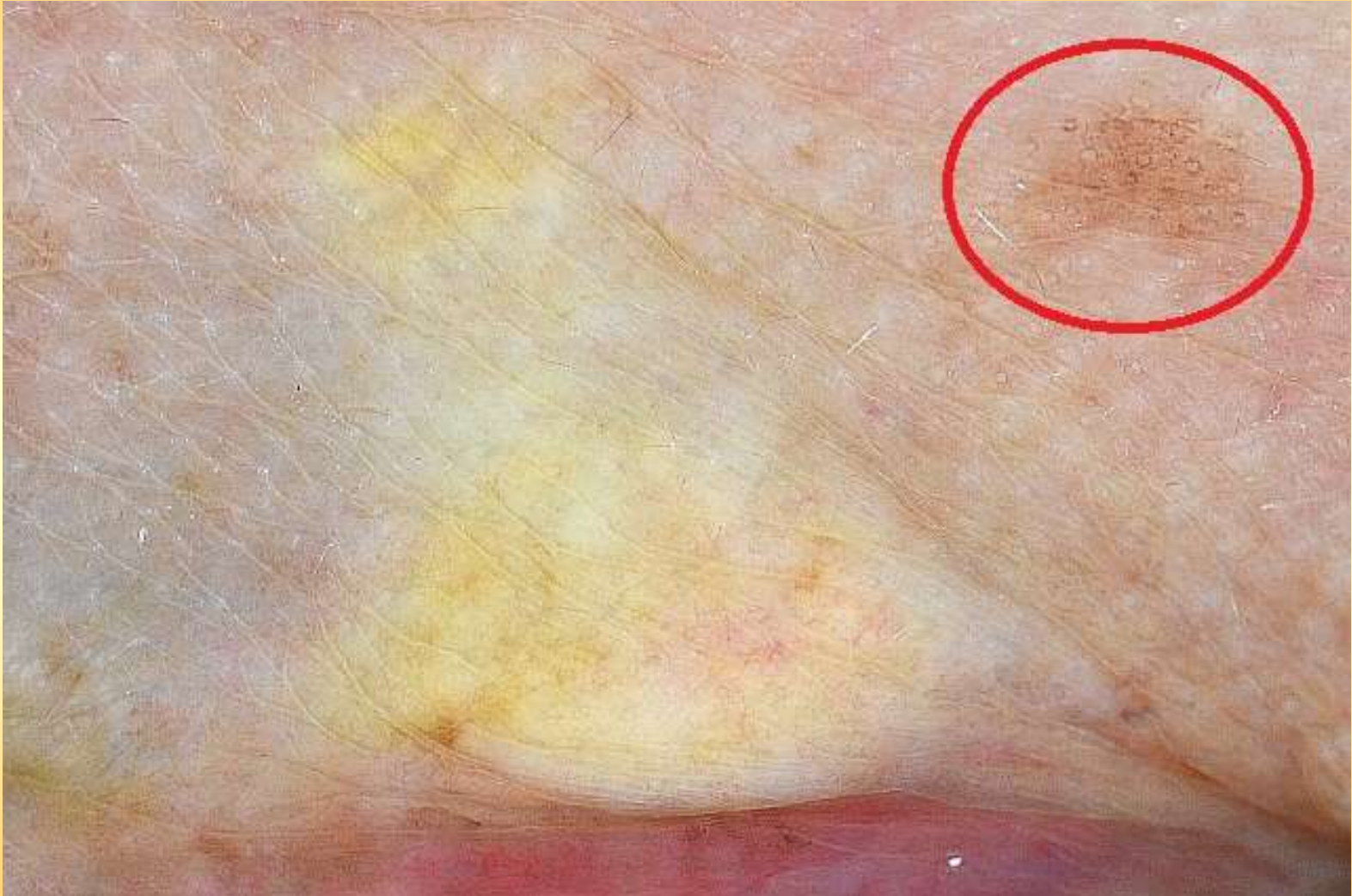Xanthelaesma palpebrarum



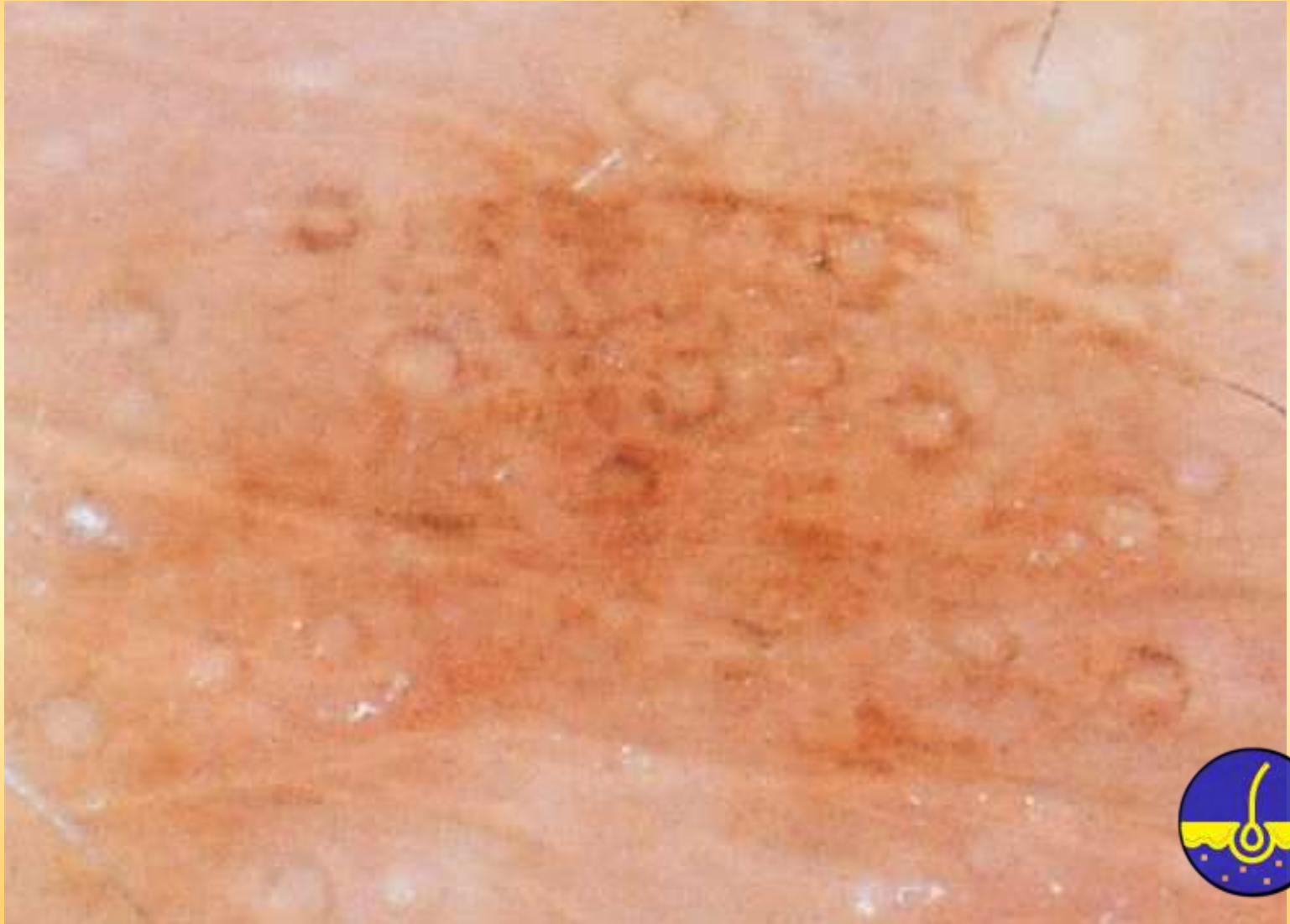
?



Solar lentigo



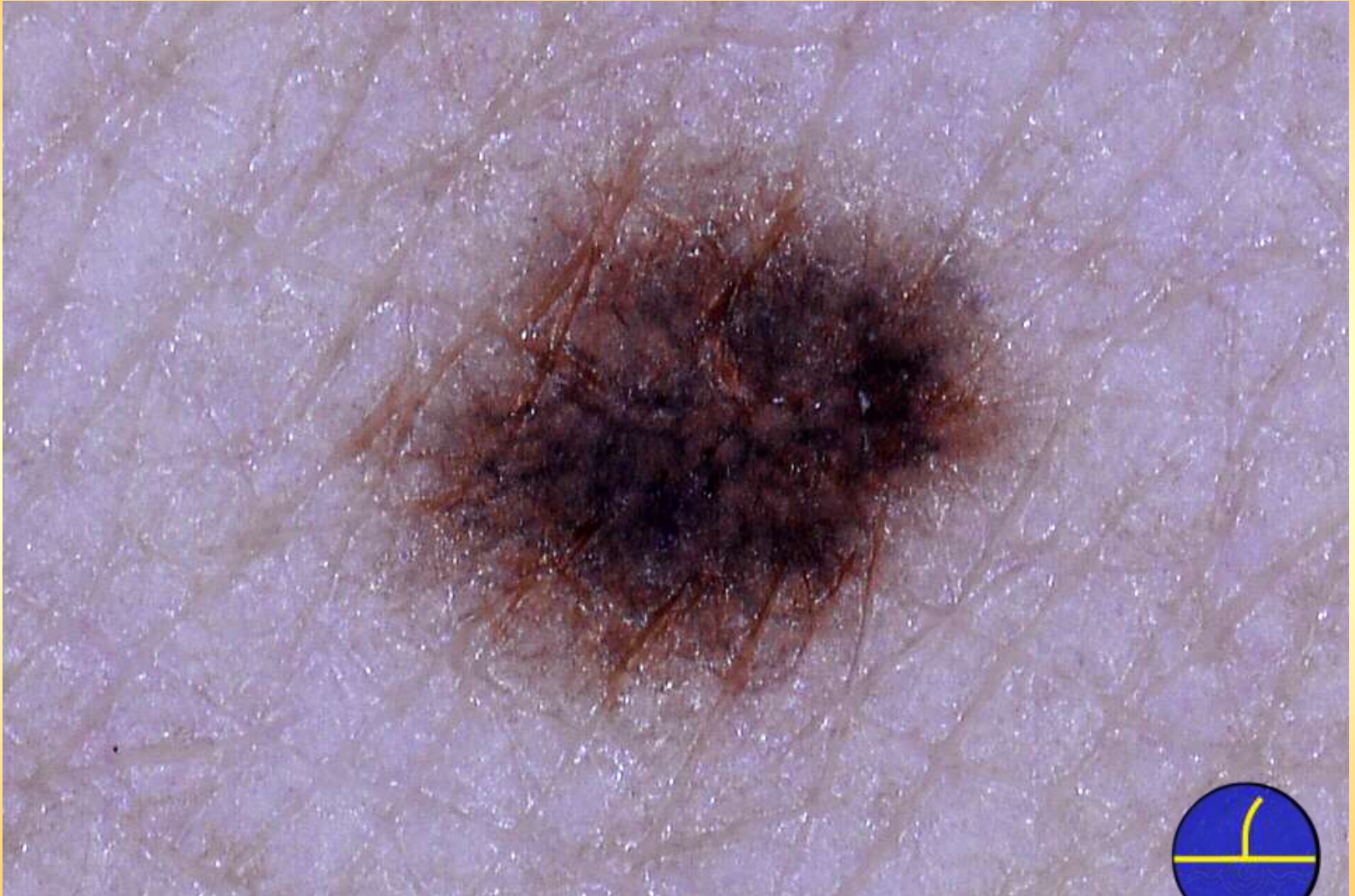
Quiz – dermoscopy



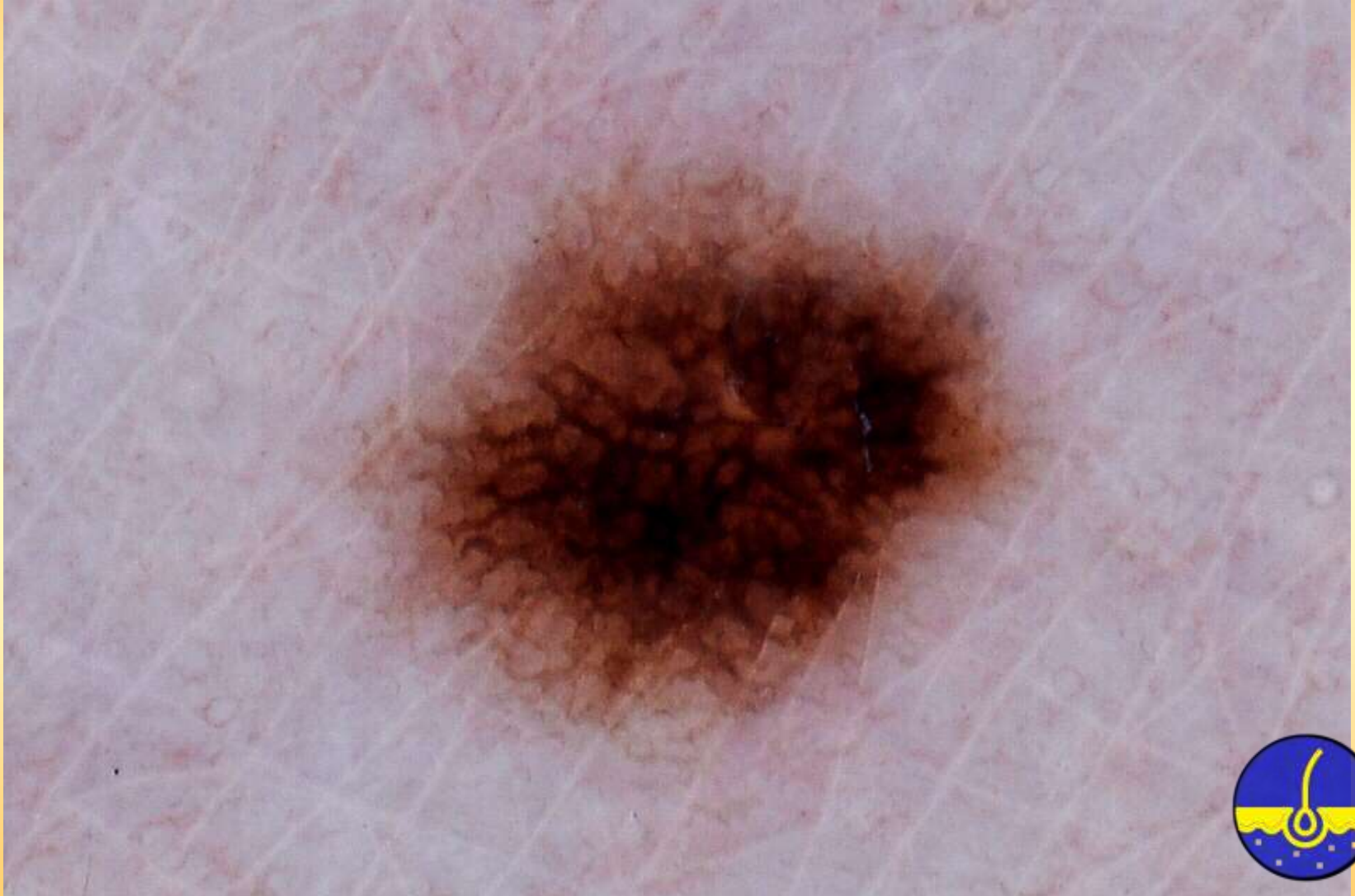
Quiz – dermoscopy



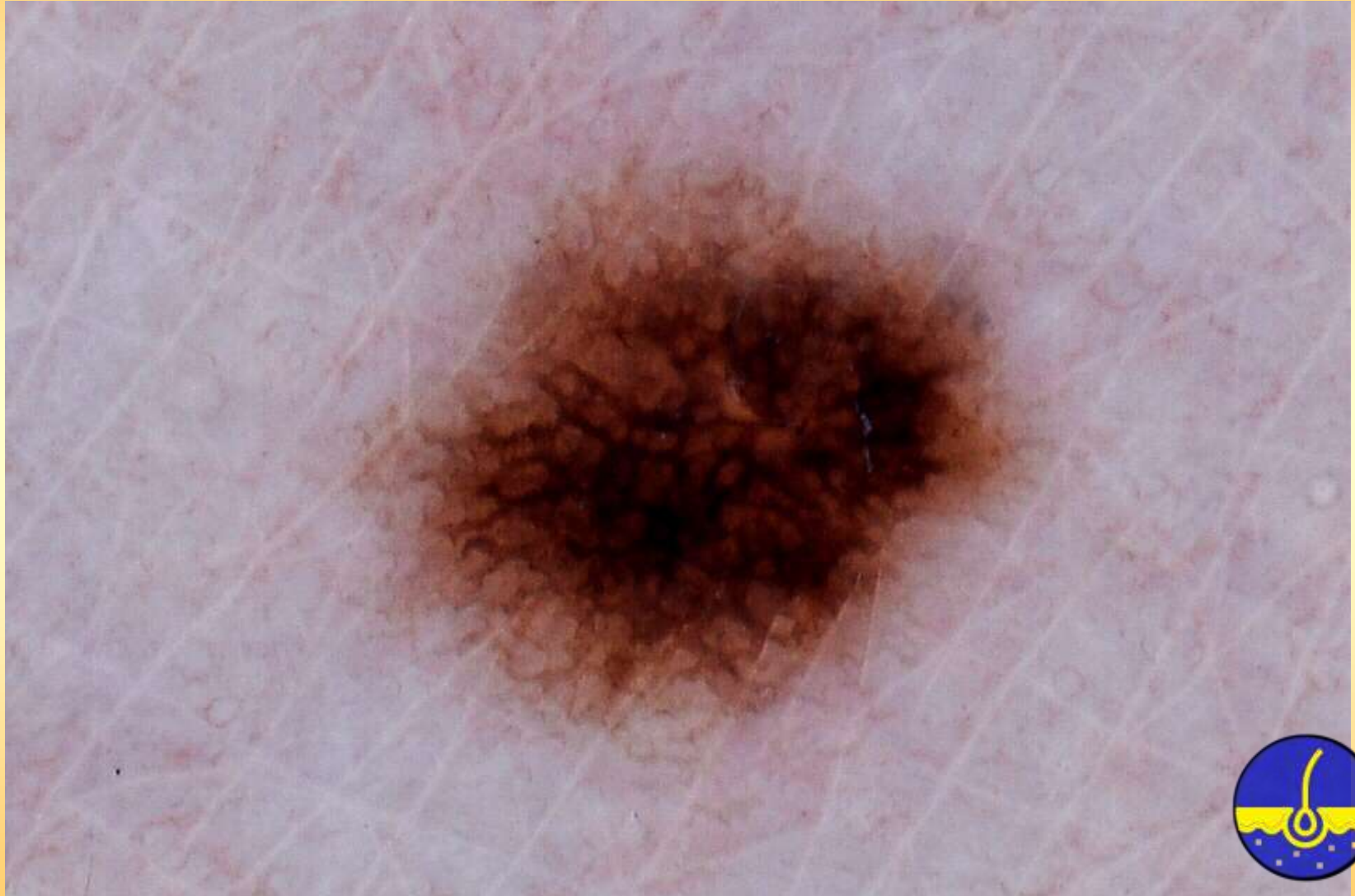
Quiz – dermoscopy



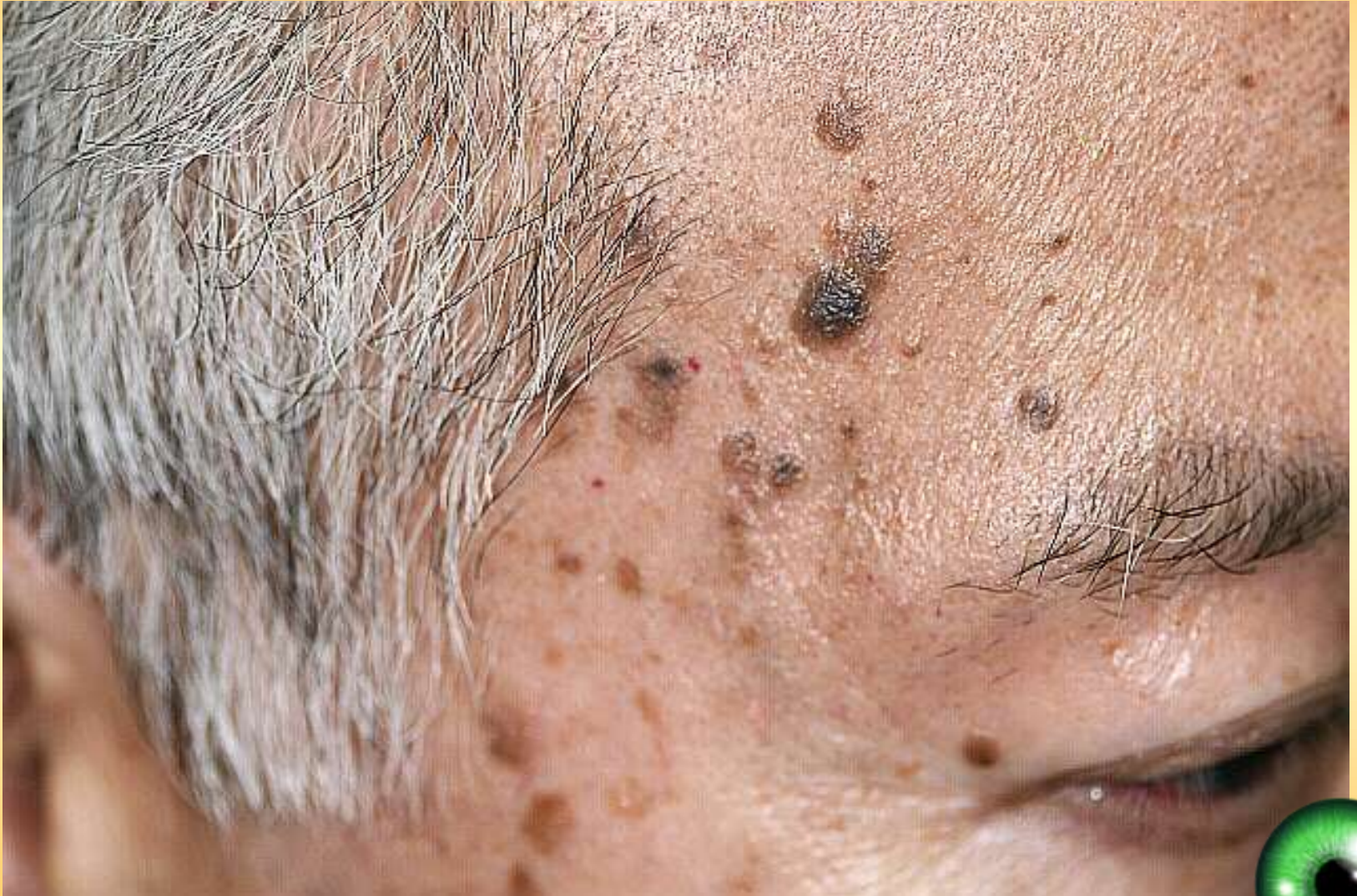?



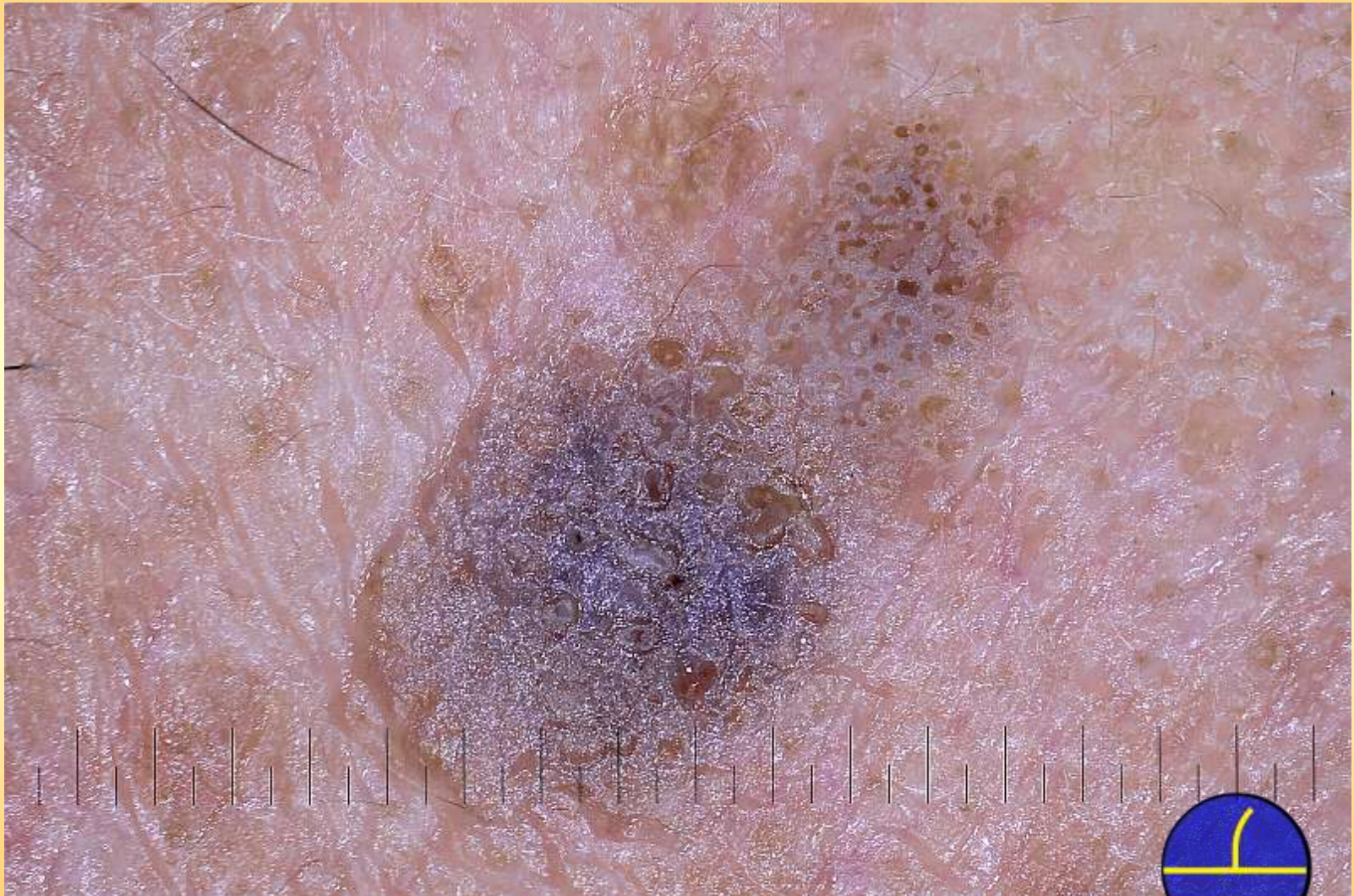Growing melanocytic naevus



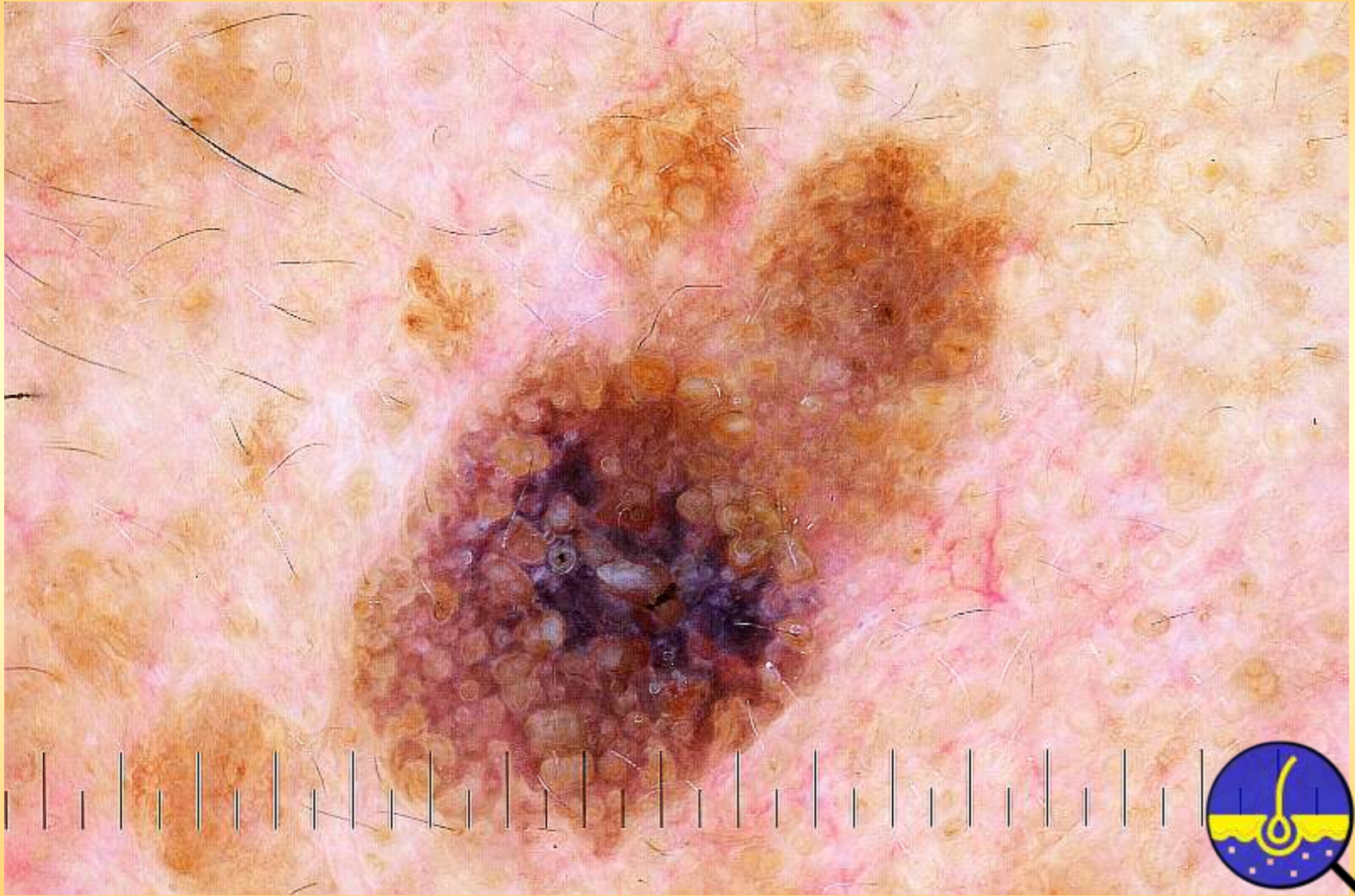
Quiz – dermoscopy



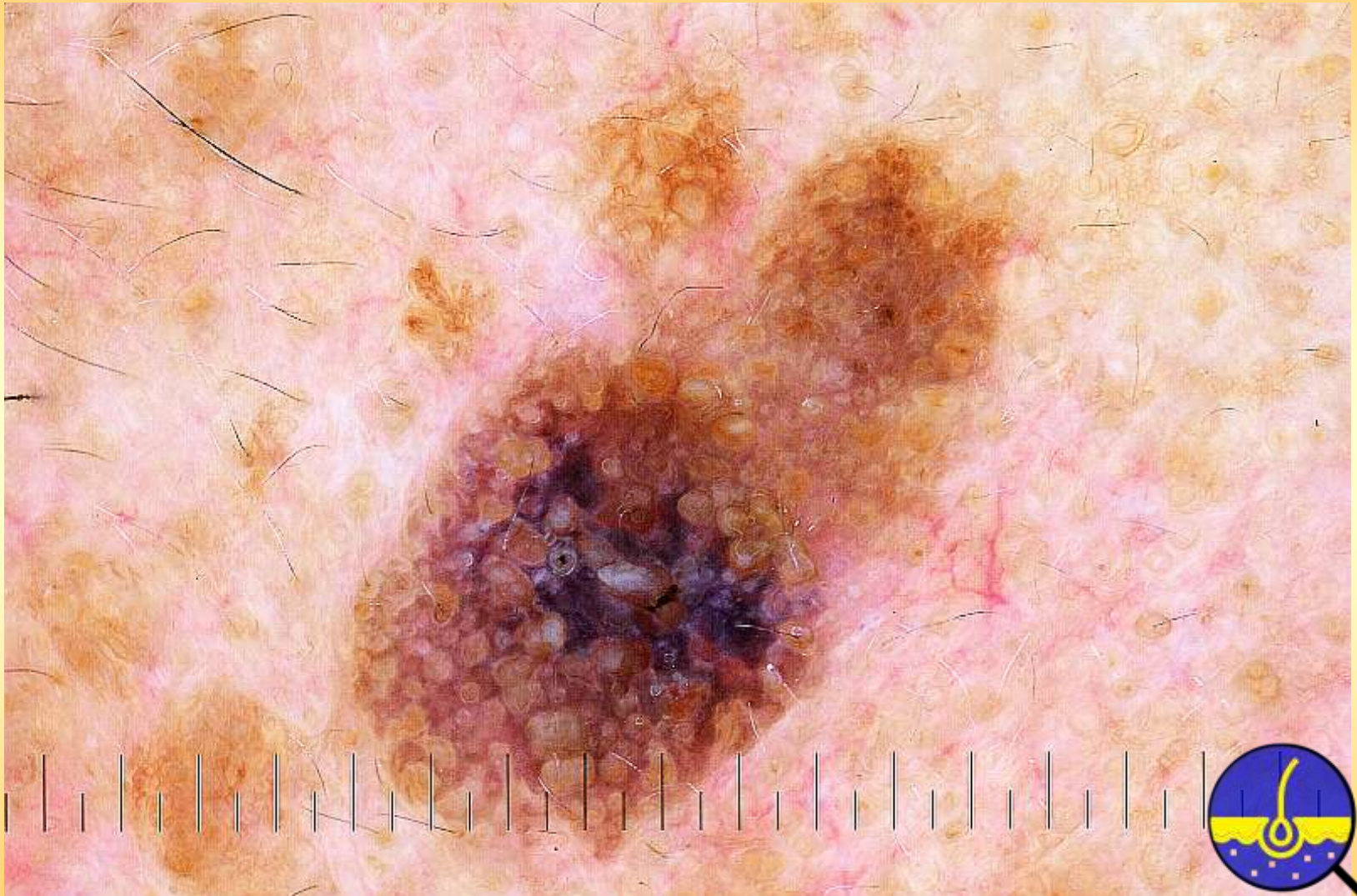
Quiz – dermoscopy



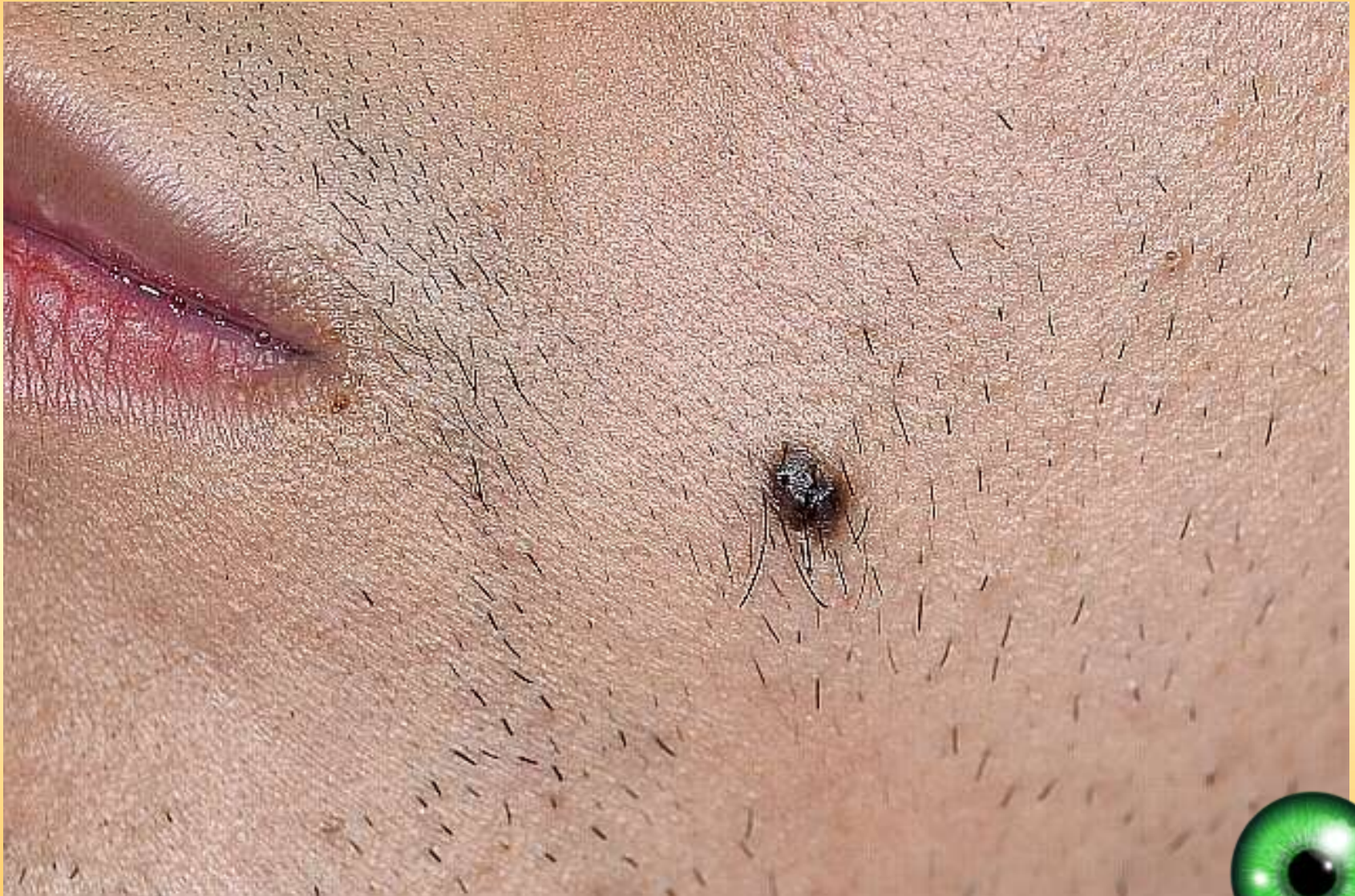?



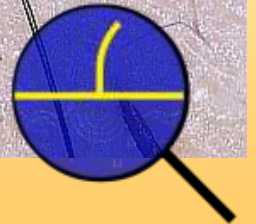
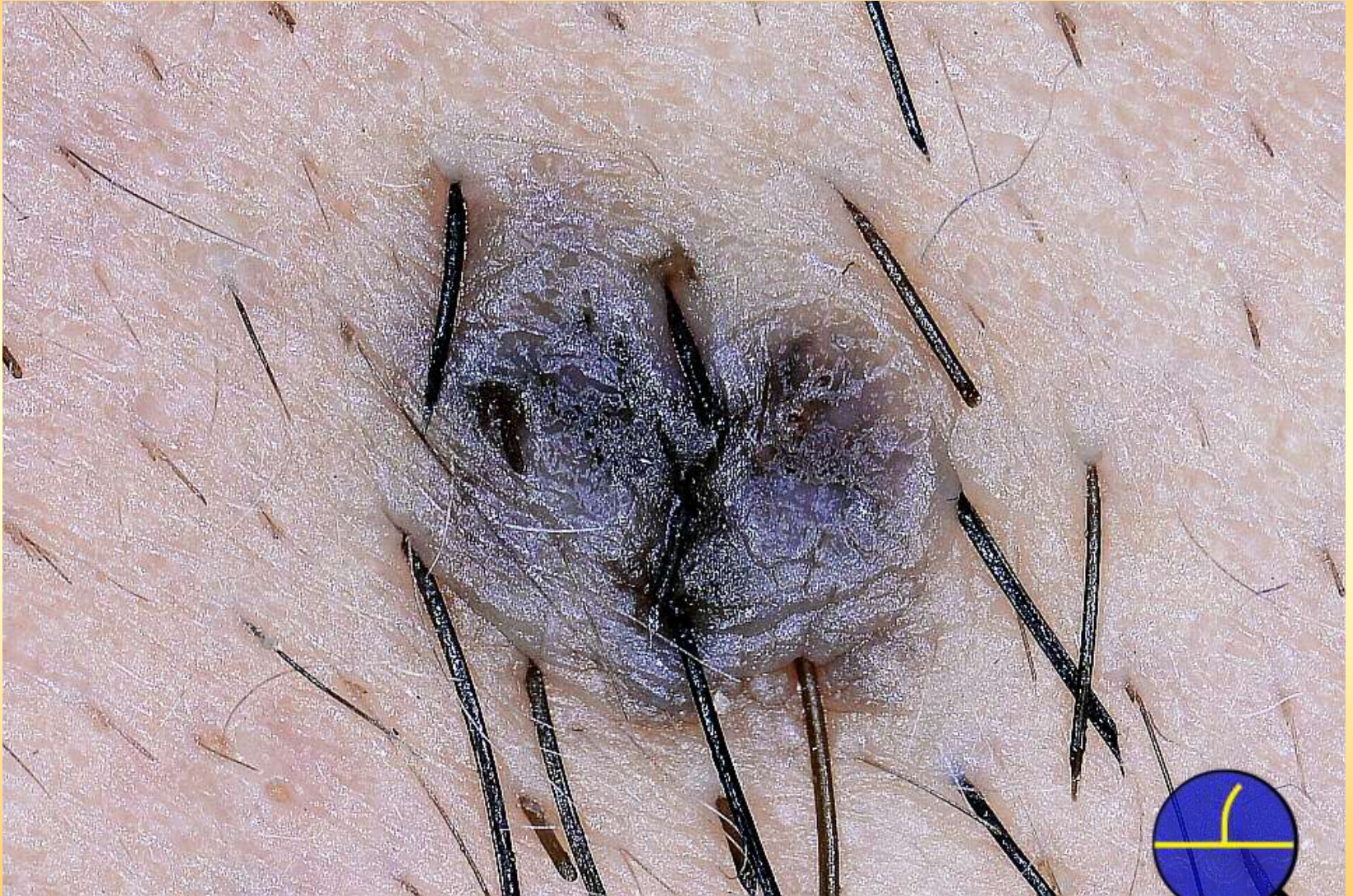Seborrhoeic keratosis



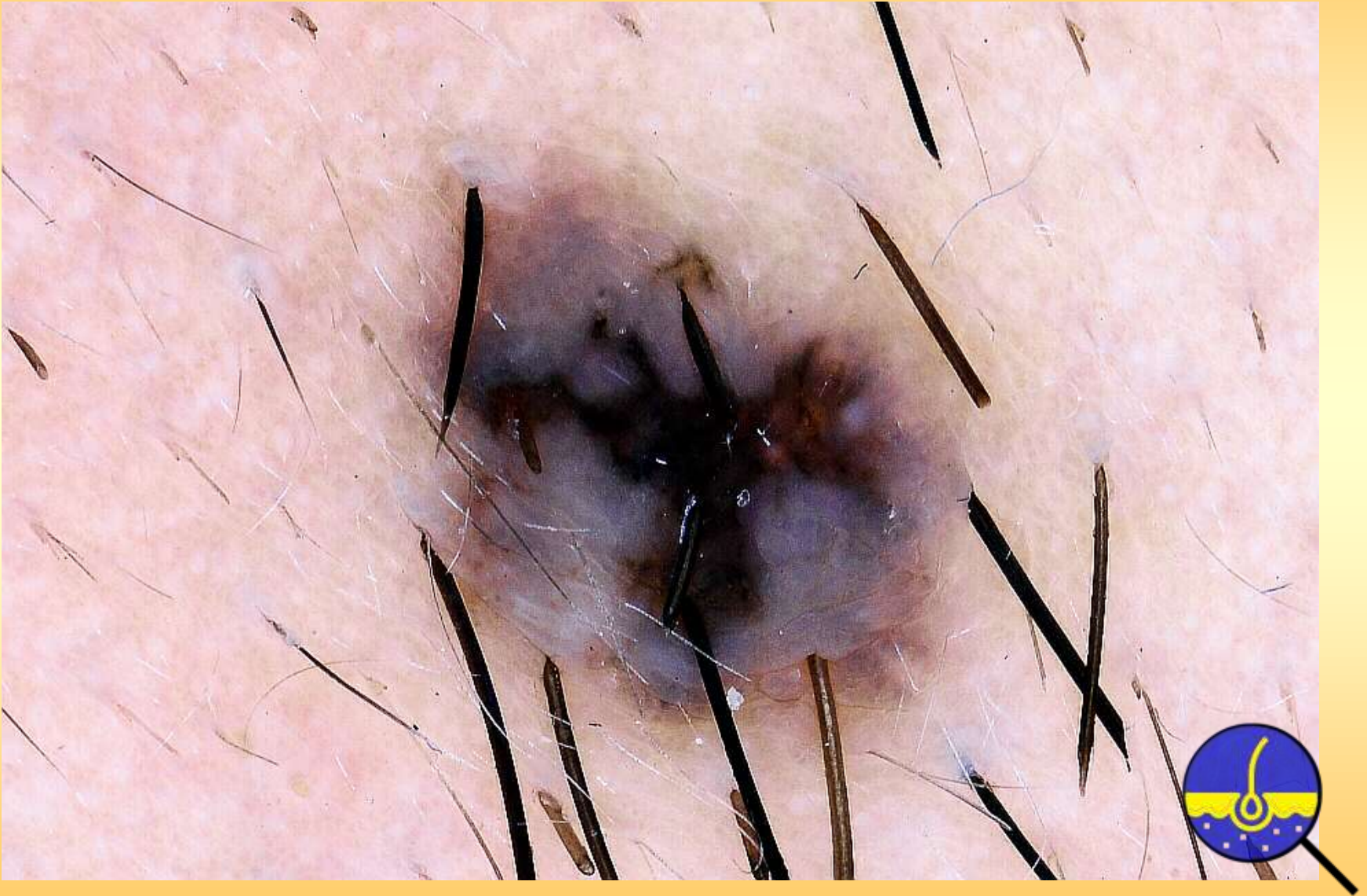Quiz – dermoscopy



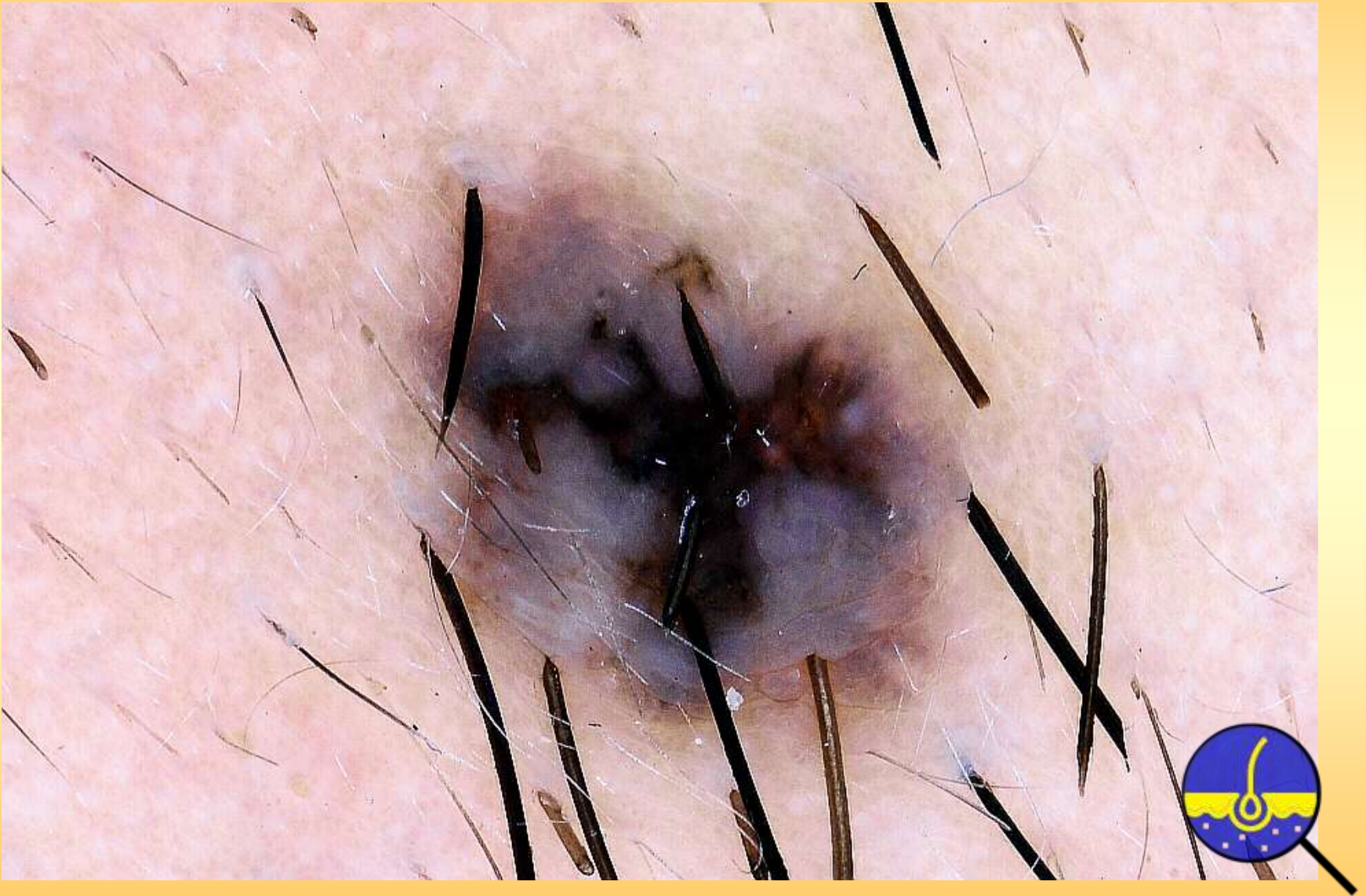Quiz – dermoscopy



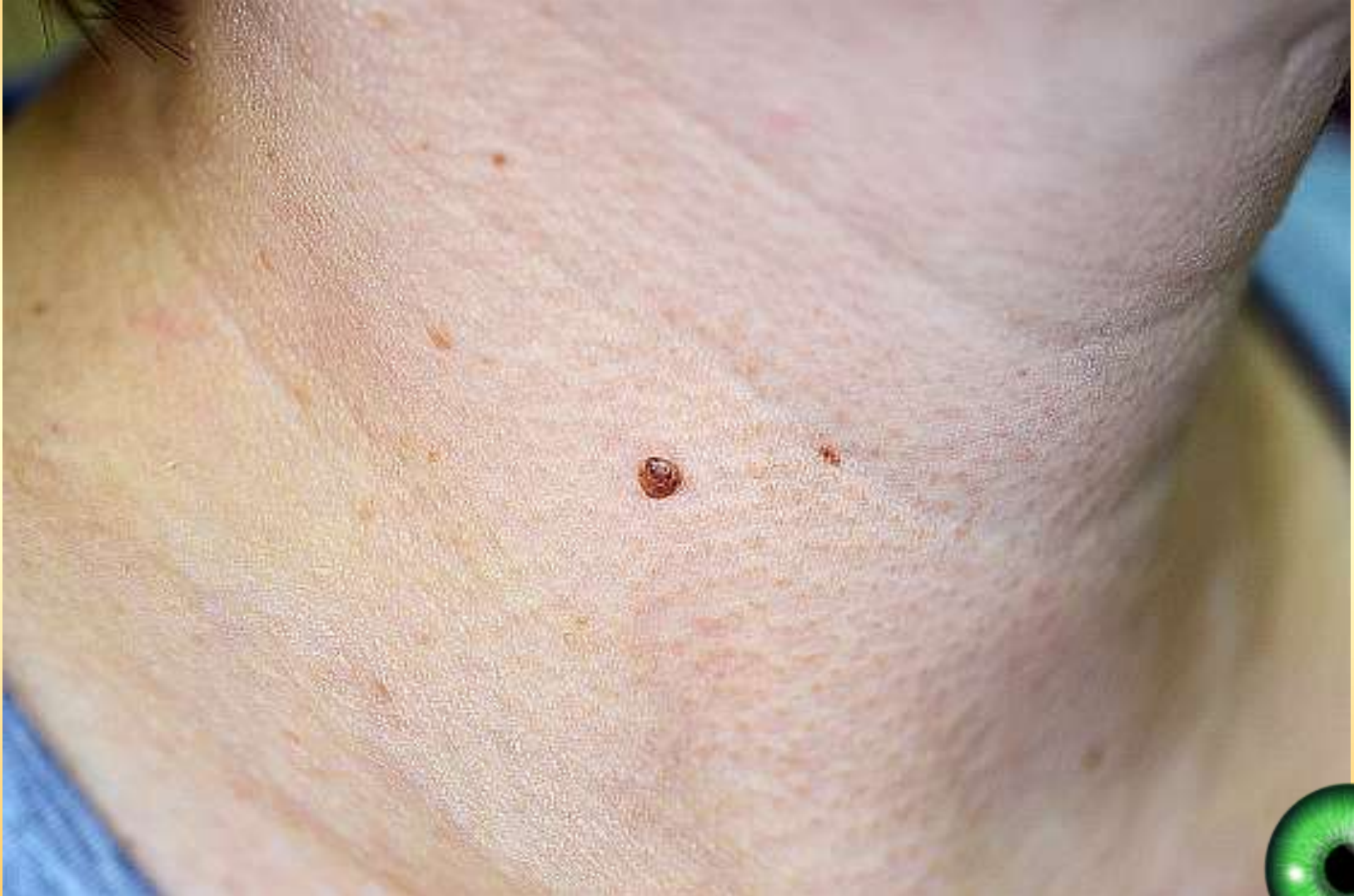?



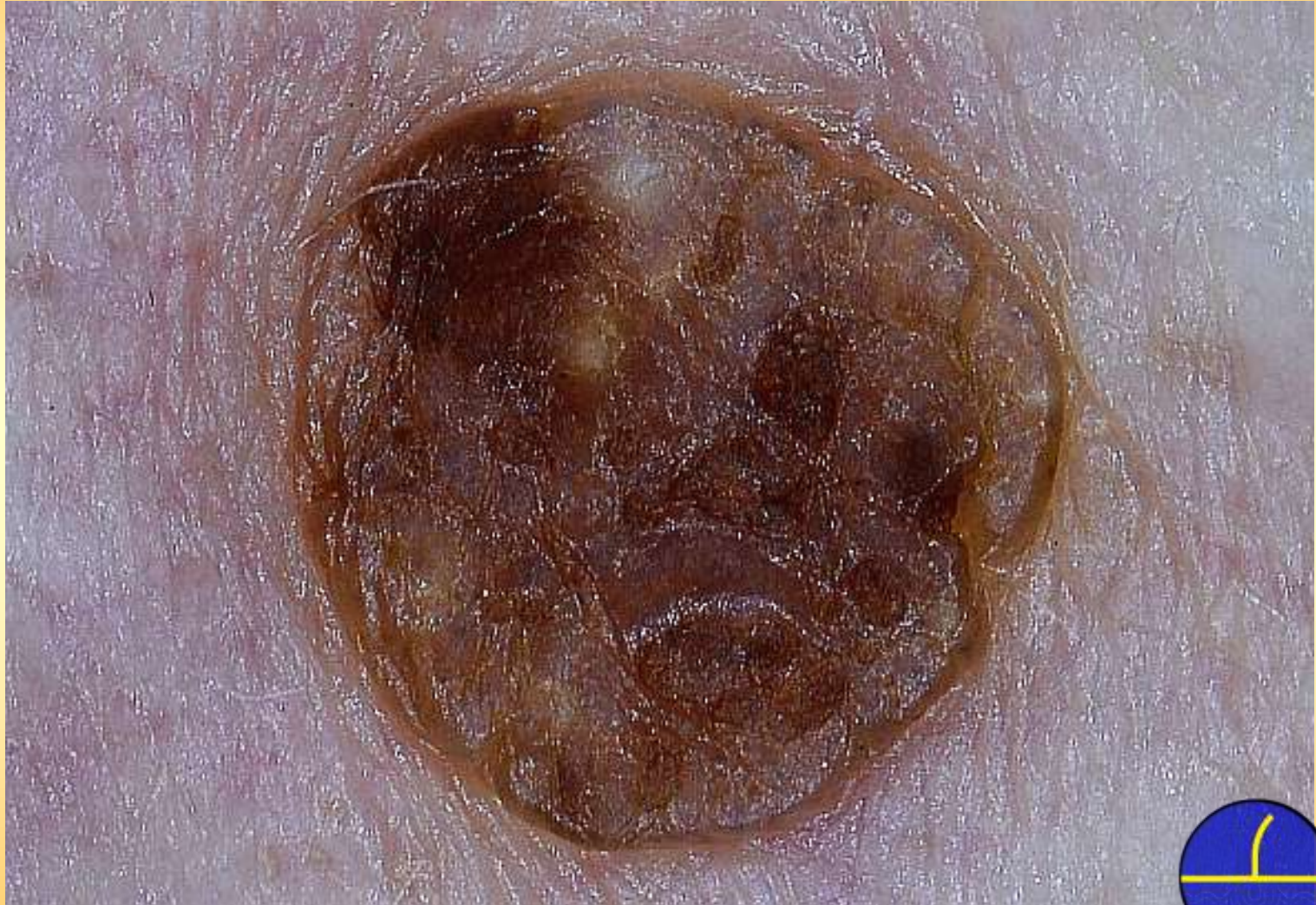Blue naevus



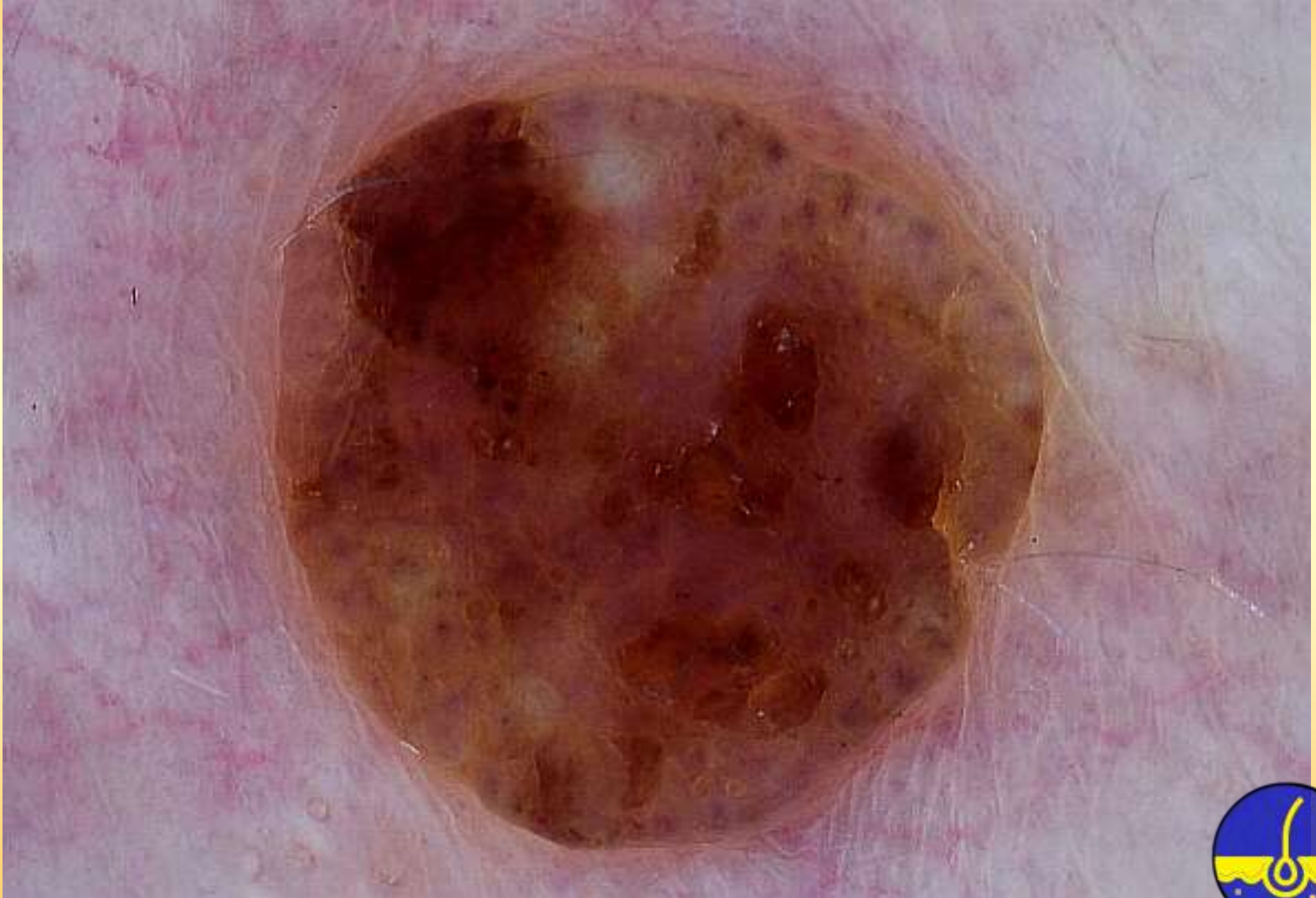Quiz – dermoscopy



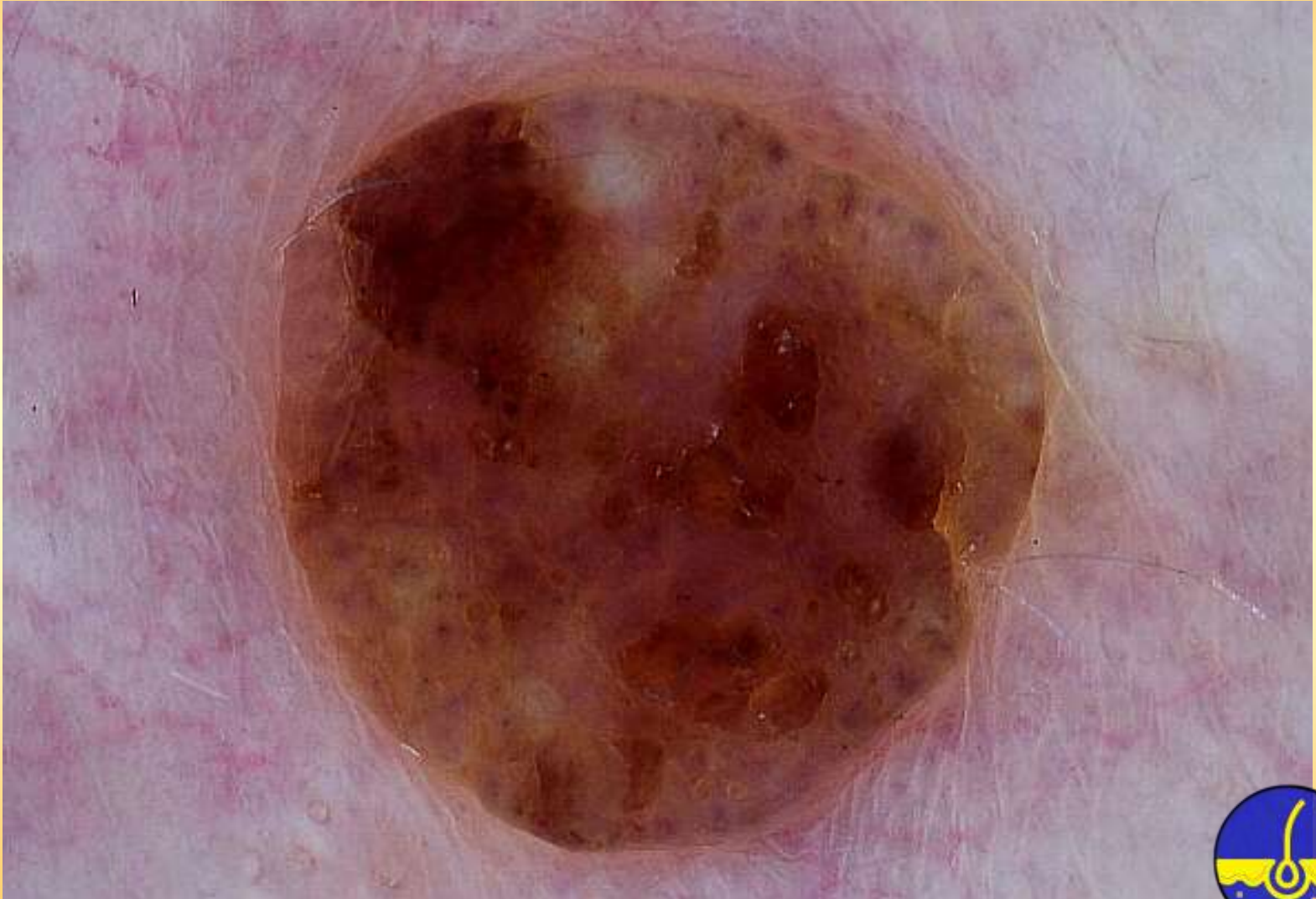Quiz – dermoscopy



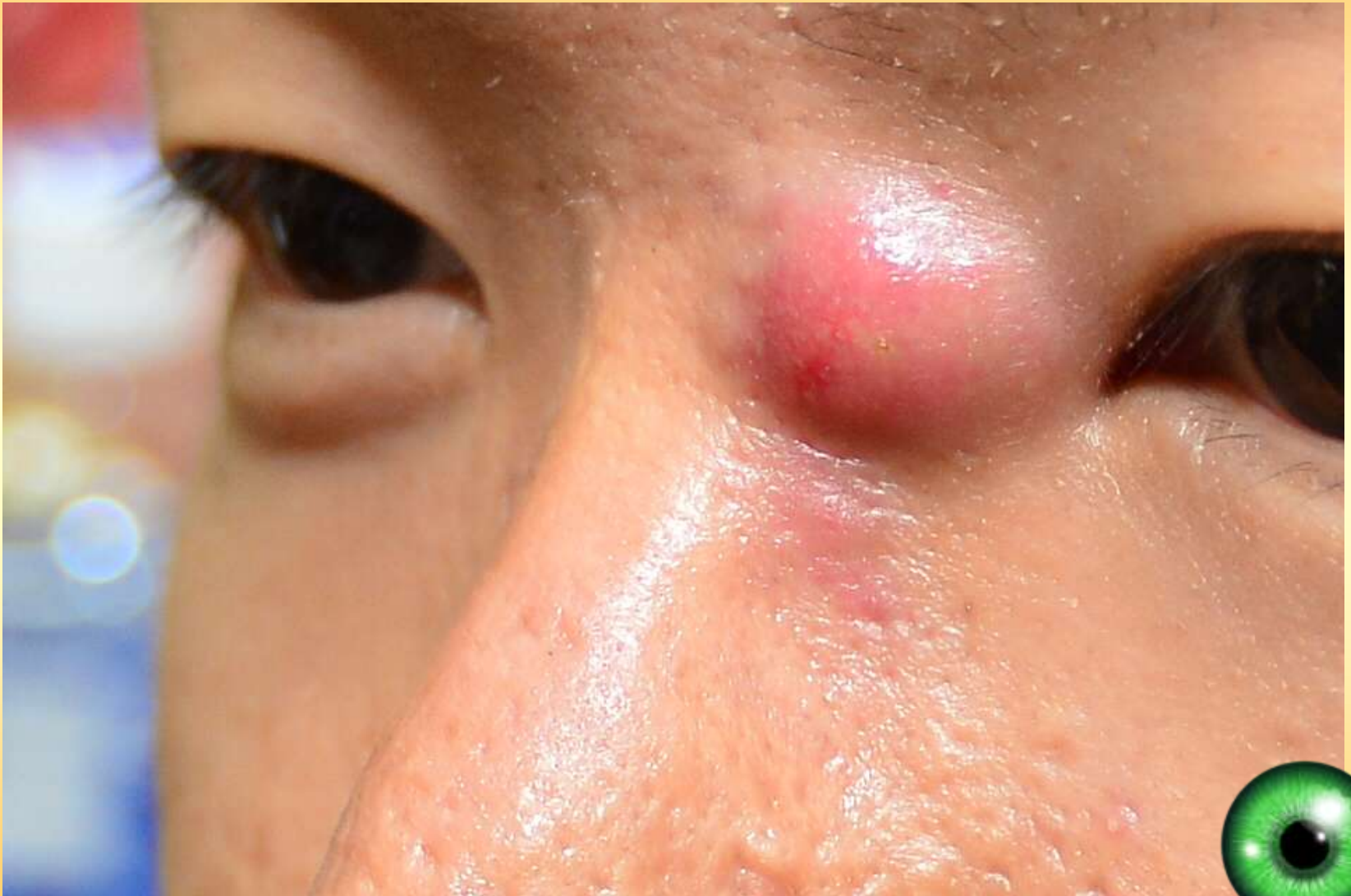?



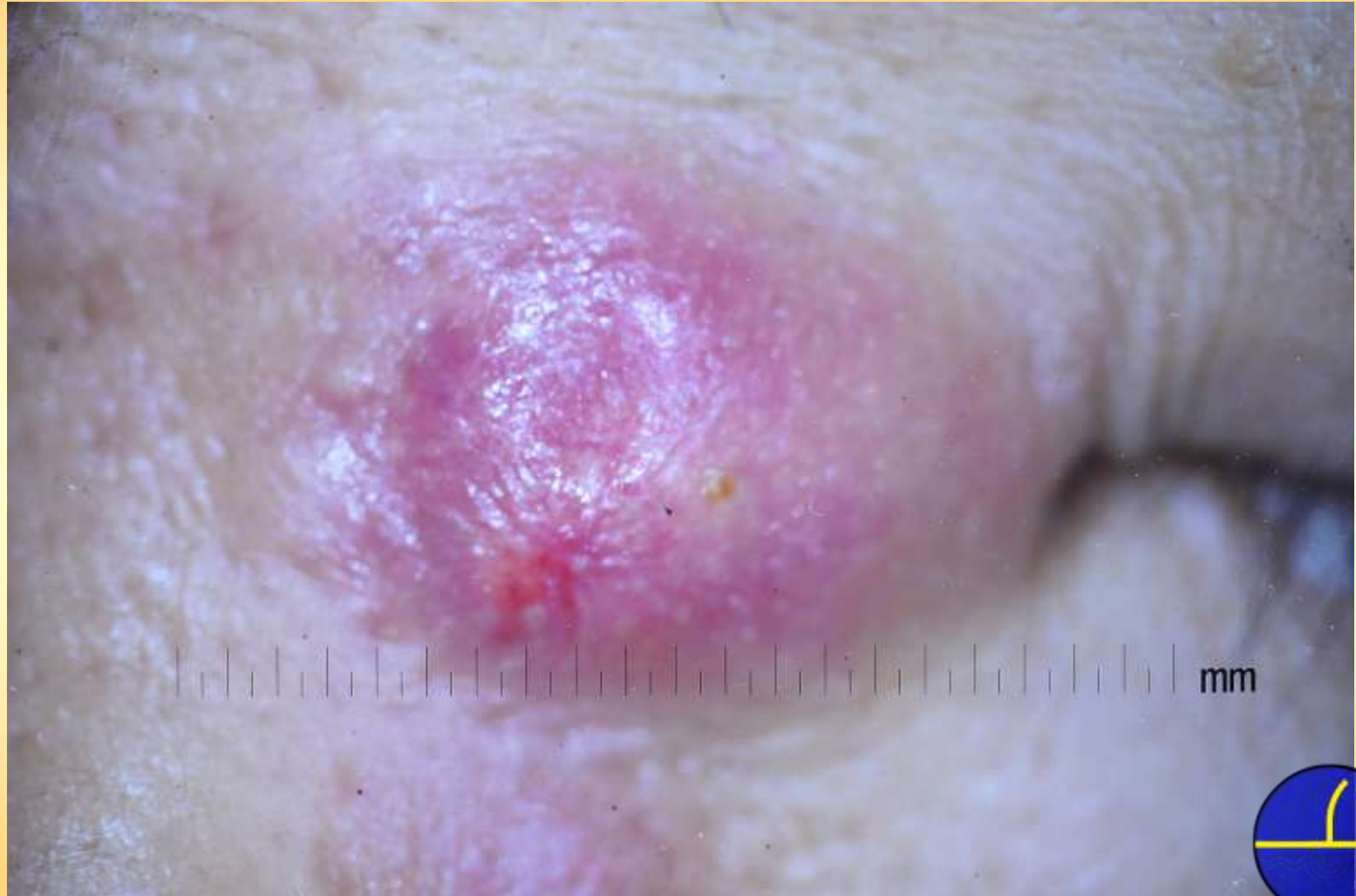Dermal naevus



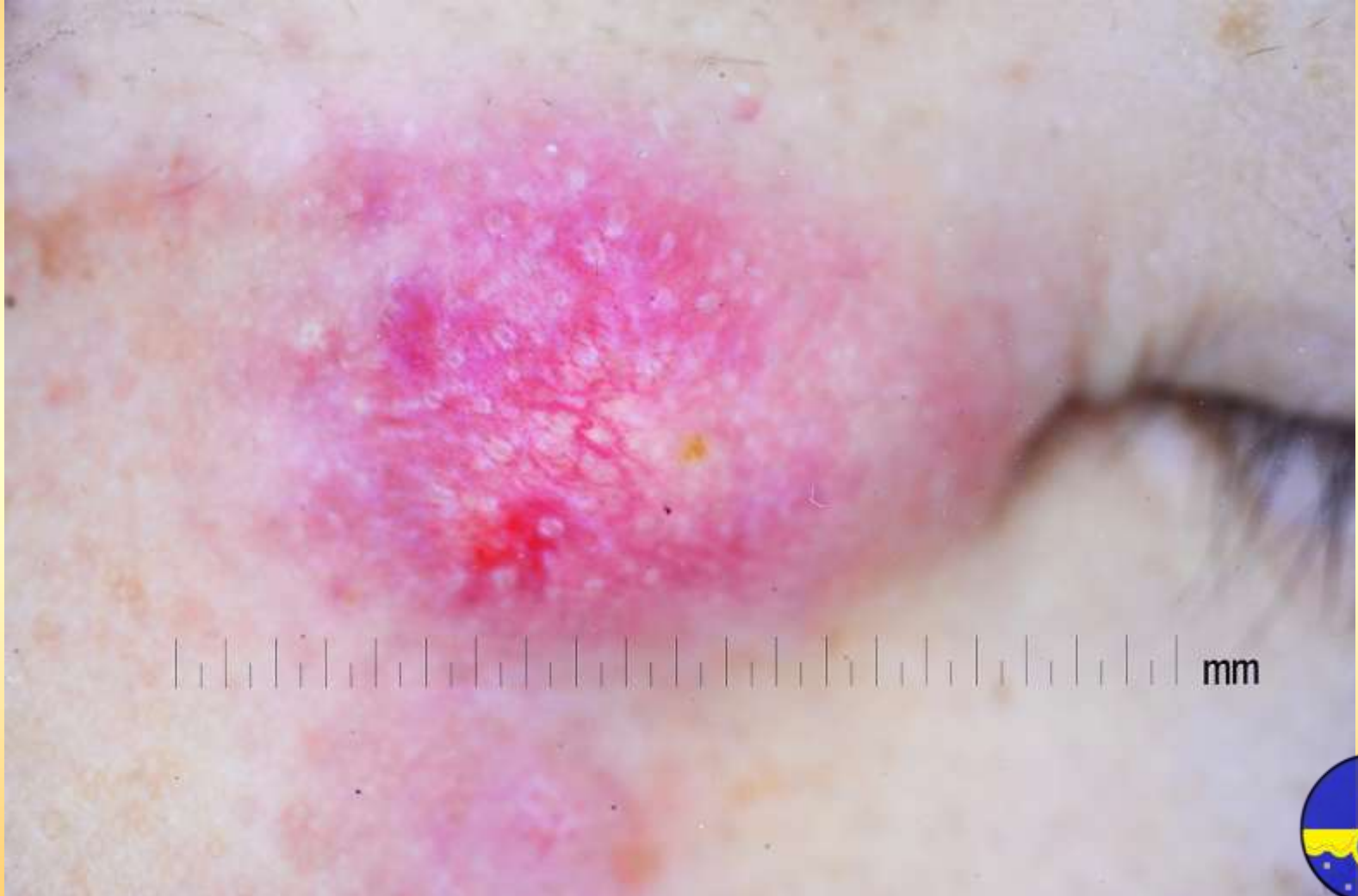Quiz – dermoscopy



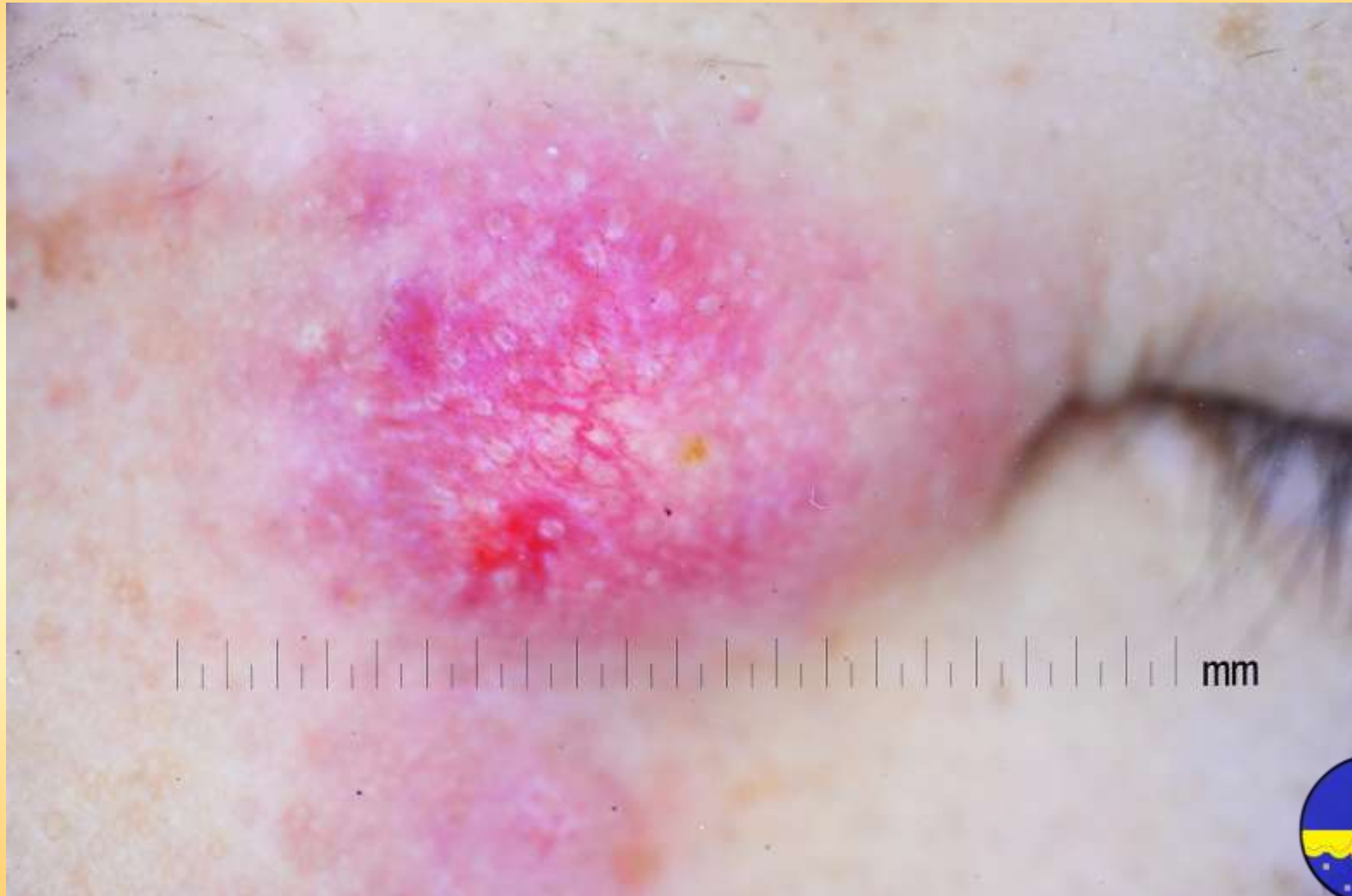Quiz – dermoscopy



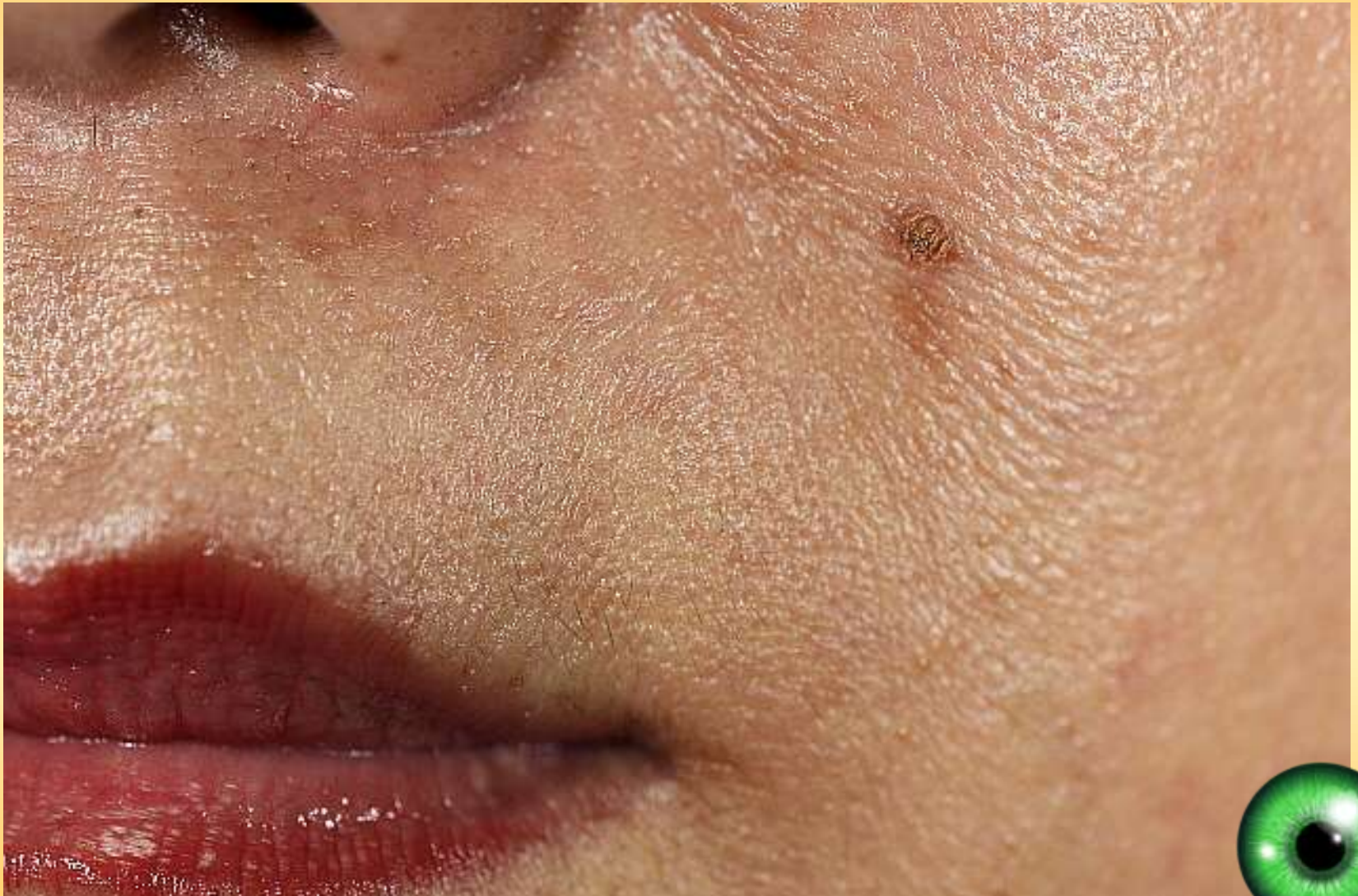?



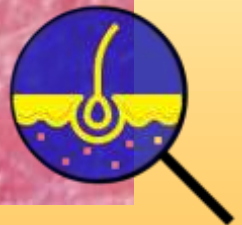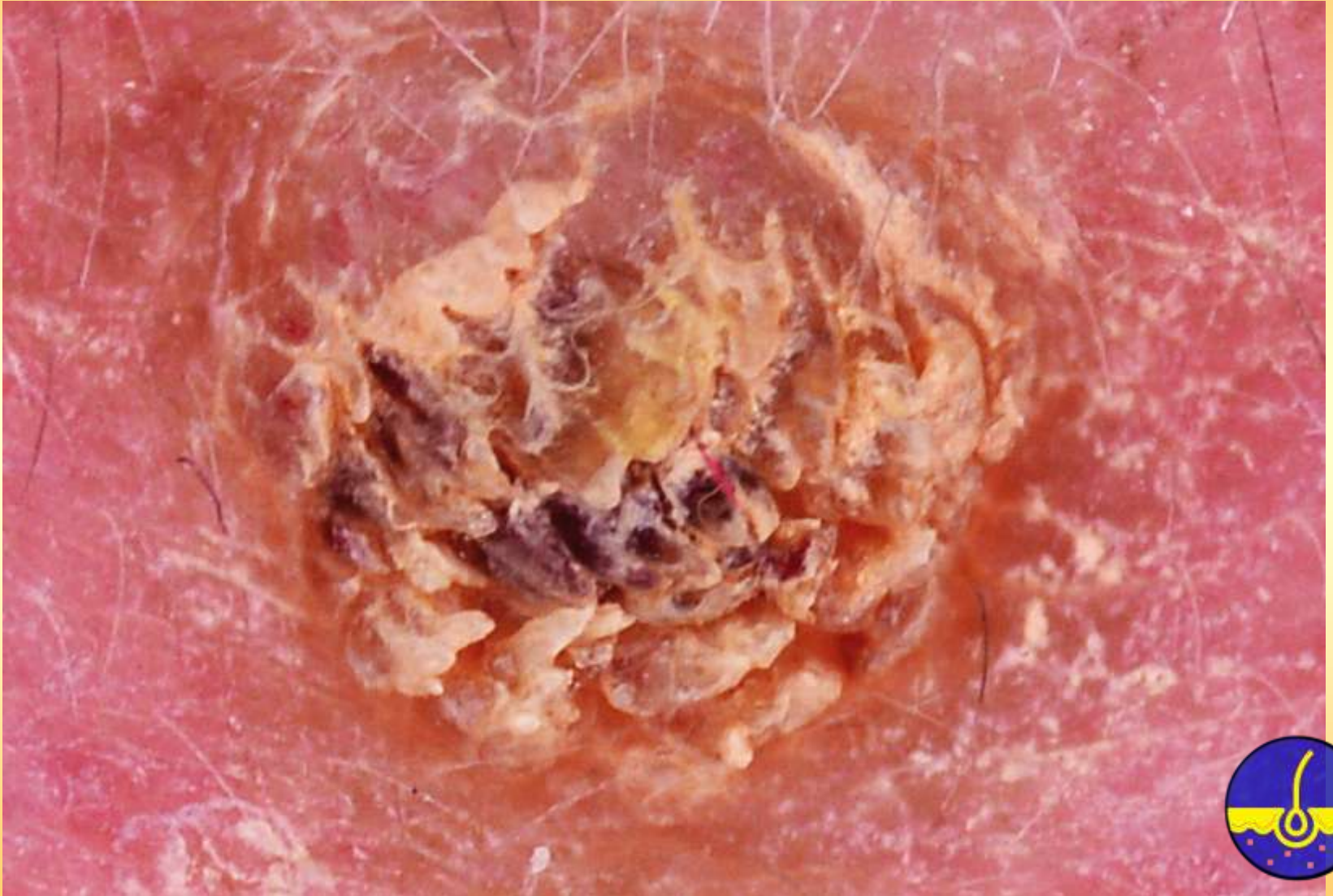Basal cell carcinoma



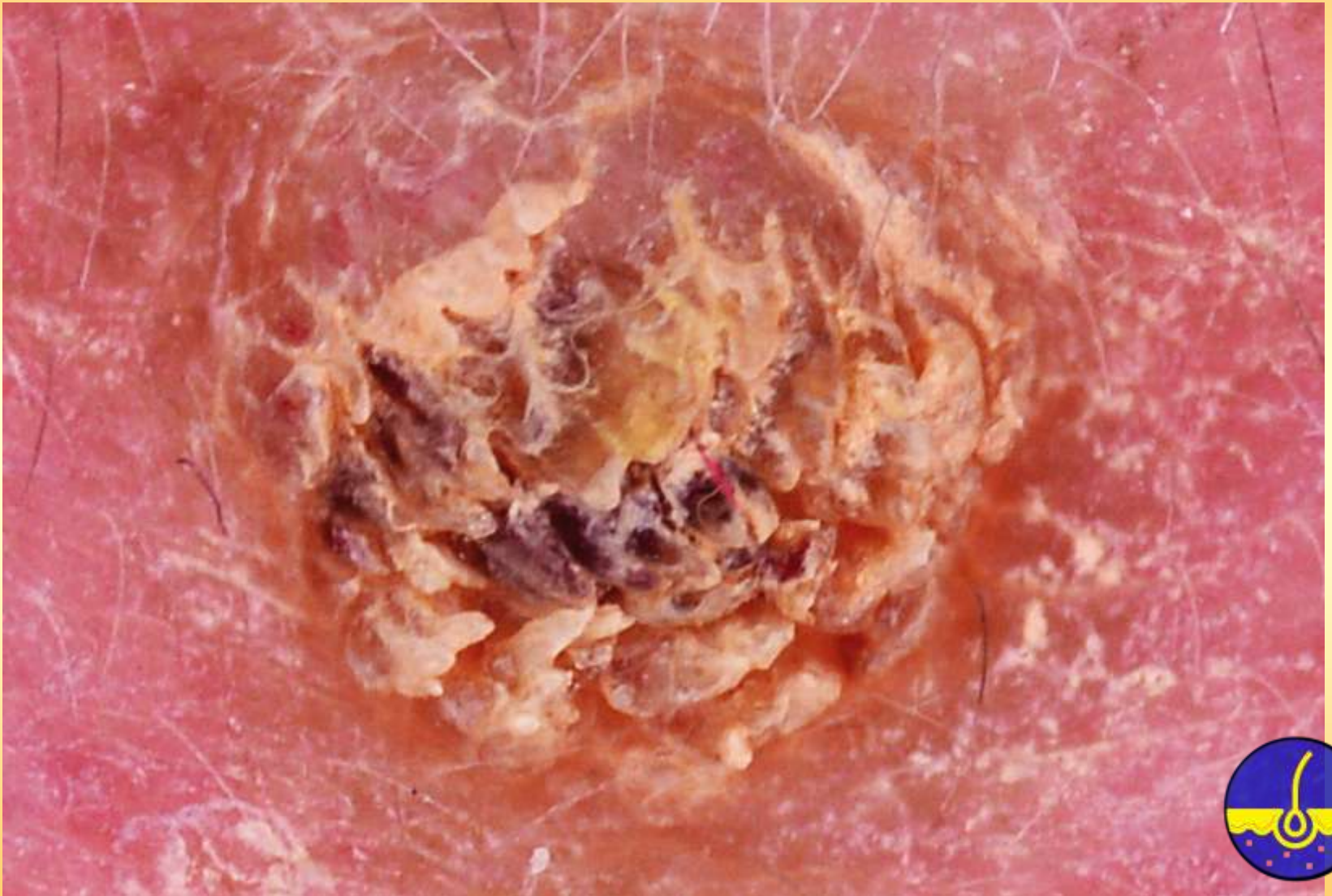Quiz – dermoscopy



?



Extragenital viral wart





THANK YOU!



HKSPCD

Hong Kong Society of Primary Care Dermoscopy

hkspcd@gmail.com